



Diagnose and Protect your acid-free stomach

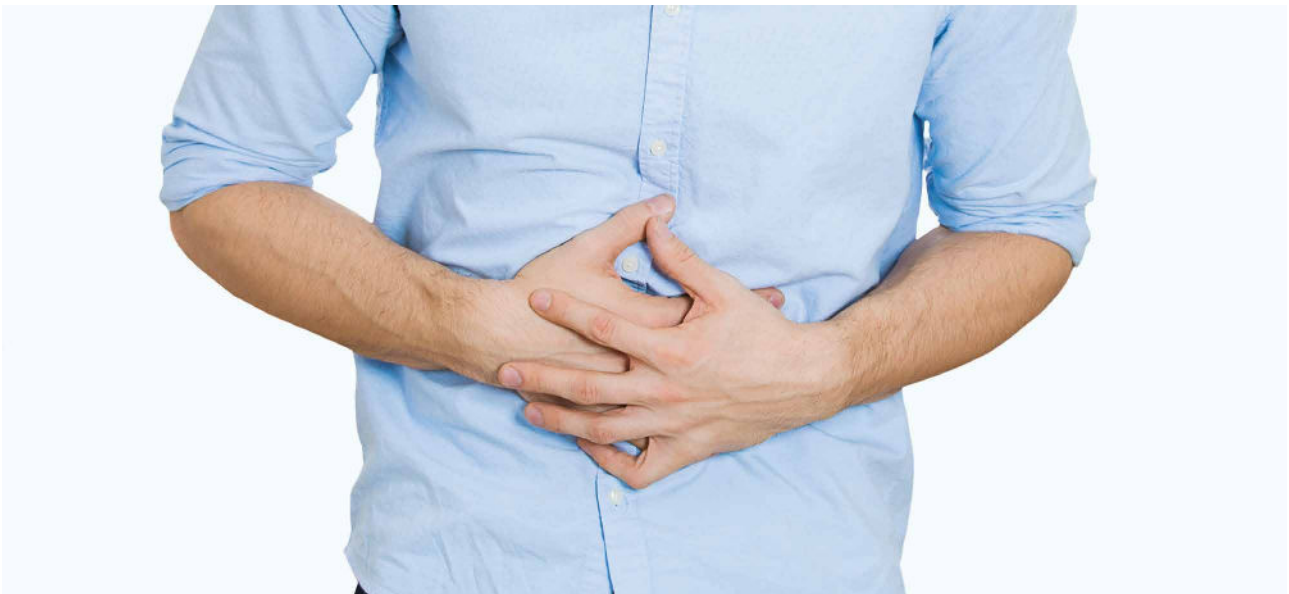**GastroPanel® for Diagnosis and
Acetium® Capsule for Protection
of an Acid-Free Stomach**

BIOHIT HealthCare

Innovating for Health

CONTENTS

SUMMARY	3
1. INTRODUCTION	4
2. SUBJECTS AT RISK FOR AG/AAG AND ITS CLINICAL SEQUELS	4
2.1. Elderly people	4
2.2. Patients with autoimmune diseases (AITD, DM1)	4
2.3. Patients with Helicobacter pylori infection	5
3. SUBJECTS AT RISK FOR INCREASED EXPOSURE TO ACETELDEHYDE	5
3.1. Cigarette smokers, alcohol drinkers	5
3.2. ALDH2 mutation	5
3.3. Chronic users of PPI medication	5
4. MONITORING THE PATIENTS WITH AG/AAG AND THOSE WITH INCREASED EXPOSURE TO ACETALDEHYDE	5
4.1. GastroPanel® test	6
4.2. Interpretation of the GastroPanel® results	6
5. ACETIUM® CAPSULE FOR PROTECTION OF ACID-FREE STOMACH	6
5.1. Acetium® capsule effectively eliminates acetaldehyde in the stomach	6
5.1.1. Elimination of acetaldehyde in subjects with acid-free stomach	7
5.1.2. Elimination of acetaldehyde in patients with AG	7
5.1.3. Acetaldehyde elimination, ALDH2 mutation and PPI-treatment	7
6. CONCLUSIONS	7
6.1. GastroPanel® biomarker test for monitoring of the high-risk subject	7
6.2. Acetium® Capsule for protection of the stomach against carcinogenic acetaldehyde	7
REFERENCES	8



GastroPanel® for Diagnosis and Acetium® Capsule for Protection of an Acid-Free Stomach

SUMMARY

The two main causes of atrophic gastritis (AG) are *Helicobacter pylori* (HP) infection and autoimmune disease. Both autoimmune AG (AAG) and AG are associated with severe clinical sequels, including malabsorption of vitamin-B12, calcium, iron, magnesium, and zinc, with potential to develop irreversible neurological complications. HP-infection is the other causative agent of AG, and together, HP and AG/AAG are the two main risk factors of gastric cancer (GC). ([www.biohithealthcare.com/links: state of the art diagnosis of Heliobacter pylori](http://www.biohithealthcare.com/links:state-of-the-art-diagnosis-of-Helicobacter-pylori), www.biohithealthcare.com/additional-information)

It is currently possible to diagnose HP-infection and AG/AAG reliably by using serological testing with a panel of biomarkers (**GastroPanel®**, Biohit Oyj, Finland): pepsinogen I (PGI), pepsinogen II (PGII), gastrin-17 (G-17) and HP-antibodies (www.gastropanel.com). Severe AG/AAG leads to **acid-free stomach** colonized by HP and other bacteria, producing **acetaldehyde** (Group I human carcinogen; IARC). Together with other conditions leading to a) acid-free stomach (e.g. **chronic users of PPI medication**) or b) those exposing the subjects to increased concentrations of acetaldehyde (e.g. cigarette smokers, alcohol intake, ALDH2 enzyme mutations), these subjects are at high-risk for GC and esophageal cancer.

This communication introduces the dual concept how to i) monitor these high-risk patients with the non-invasive GastroPanel® test to disclose an early risk of GC, and how to ii) protect the **acid-free stomach** of these high-risk subjects by a novel formulation (Acetium® Capsule, Biohit Oyj) based on slow-release L-cysteine, effectively **eliminating carcinogenic acetaldehyde** (www.acetium.com).

Acetium® Capsule is a novel formulation of slow-release L-cysteine, being a unique medical device designed to **elimination of carcinogenic acetaldehyde** in an acid-free stomach by forming a stable inactive compound: 2-methylthiazolidine carboxylic acid (MTCA). Regular use of Acetium® Capsule is indicated for all those who have **acid-free stomach** of any cause, **chronic PPI-users** included. The efficacy of Acetium® Capsule in acetaldehyde elimination has been confirmed in placebo-controlled clinical trials where slow-release L-cysteine effectively (by 60–80%) eliminated acetaldehyde in patients with acid-free stomach due to AG or **PPI treatment**, similarly in subjects with active or deficient ALDH2 enzyme.

With a rational use of these two medical devices, one can diagnose the gastric high-risk conditions and subsequently **protect the acid-free stomach** against exposure to **carcinogenic acetaldehyde** ([www.biohithealthcare.com/links: State of the art GastroPanel and Acetium innovations for the unmet need](http://www.biohithealthcare.com/links:State-of-the-art-GastroPanel-and-Acetium-innovations-for-the-unmet-need)).

1. INTRODUCTION


Atrophic gastritis (AG) in the stomach body (corpus) leads to decreased gastric acid output and eventually **acid-free stomach**. The age-specific prevalence of AG increases with age, reaching 8% among people over 70 years of age (2). In most cases, achlorhydria remained undiagnosed, and 13% of them used PPI medication regularly (2,3). AG develops by two different mechanisms: 1) as a result of *Helicobacter pylori* (HP) infection, and 2) through an autoimmune mechanism (4,5). In 1994, IARC declared HP-infection as carcinogenic to humans (6). Indeed, the two major risk factors of gastric cancer (GC) are HP-infection and AG. The relative risk of GC increases in parallel with increasing severity and extent of AG (7-12). In addition to increasing the risk of GC, AG is associated with a wide variety of clinical sequels, many of which causing **significant comorbidity** particularly among elderly people (13,14). As the output of gastric acid is reduced, absorption of vitamin-B12, iron, calcium, zinc and some drugs is impaired (13,14). **Iron deficiency anemia** and **osteoporosis** are the clinically most relevant consequences of iron and calcium malabsorption, respectively, among the subjects with **acid-free stomach** (13). At present, an increasingly important group of subjects with acid-free stomach is composed of patients who are **chronic users of PPI-medication** (10-14).

Autoimmune atrophic gastritis (AAG) and pernicious anemia (PA) are common autoimmune diseases with respective prevalence of 2% and 0.15–1% in the general population, respectively (15-17). In patients with autoimmune thyroid disease (AITD)(18,19) and those with type 1 diabetes (DM1)

(20,21), the prevalence of AG/PA is 3- to 5-fold increased. In AAG, chronic auto-aggression against the gastric proton pump, H⁺/K⁺ATPase results in decreased gastric acid secretion and hypergastrinemia (22-24). Similar to HP-induced AG, also in AAG, PA may result from vitamin-B12 deficiency, which is up to 10 times more common in DM1 patients than in non-diabetic subjects (21,25-32). PA is a growing health concern worldwide, particularly in aged populations, leading to protean clinical manifestations: peripheral neuropathy, depression and dementia, sometimes very quickly (33,34).

Early diagnosis of AG and AAG is very important to prevent and treat iron deficiency anemia, PA, and (pre) malignant gastric lesions: intestinal metaplasia (IM), enterochromaffin-like cell (ECL) hyperplasia, and dysplasia (21). Similarly, an early detection of vitamin-B12 deficiency is the prerequisite for effective prevention of its potentially harmful clinical sequels (13,14,33,34).

The present communication is a brief introduction to a novel concept by which both an early detection of the subjects at risk is possible by using a panel of serum biomarkers (GastroPanel®), and **protection of the acid-free stomach** mucosa can be instituted by **eliminating carcinogenic acetaldehyde** with a novel slow-release L-cysteine formulation (Acetium® capsule)(35). Given the above risks of acid-free stomach, **mucosal protection by the L-cysteine formulation is certainly indicated in subjects who are chronic users of PPI-medication** (35).



2. SUBJECTS AT RISK FOR AG/AAG AND ITS CLINICAL SEQUELS

As already mentioned, there are special groups of people who are at increased risk of developing AG and acid-free stomach, with all potential clinical sequels [1-15,20-34]. After a protracted clinical course, the outcome is similar in AG caused by HP-infection and in AAG; an **atrophic gastric mucosa** is associated with an **acid-free stomach**. Apart from the well-known conditions of malabsorption [13,14,33,34], both AG and AAG predispose the subjects to increased risk of GC [26-32]. The **carcinogenic agent** in common to both AG/AAG and acid-free stomach is **acetaldehyde**, classified as Group I human carcinogen by IARC in 2009 [35,36]. Apart from HP itself which is capable of synthesizing acetaldehyde, the other bacteria colonizing in acid-free stomach, are an abundant source of this carcinogenic substance [37,38].

2.1. Elderly people

It is well known that the age-specific prevalence of AG increases with age, reaching 8% among people over 70 years [2]. To further assess the prevalence of AG and its clinical sequels in the Nordic region, we screened a cohort of 209 elderly people (mean age 82 years) by GastroPanel® and active B12-vitamin test in Finland and Estonia [39]. AG in Finland (12.3%) and Estonia (15.6%) was not different ($p=0.494$), but manifest B12-vitamin deficiency was more common in Tartu (23.3% vs. 3.8%) ($p=0.0001$). Of all known complications of AG, only i) the diagnosed vitamin-B12 deficiency (OR=3.5), and ii) diagnosed PA (OR=9.4) were significantly associated with AG. These data implicate that to prevent irreversible neurological complications, early diagnosis and adequate supplementation of vitamin-B12 deficiency are essential. This is best done by detecting the subjects at risk (i.e., those with acid-free stomach) by targeted GastroPanel® screening, even years before the development of protean clinical manifestations [35, 39, 40-43].

2.2. Patients with autoimmune diseases (AITD, DM1)

In patients with AITD and DM1, the prevalence of AAG/PA is increased up to 3- to 5-fold [15-23]. AAG may predispose to GC or carcinoid tumor [15-23]. The association of AITD and other autoimmune diseases was first suggested in the 1960's [19]. More recently, the association between AITD and PA has been included in type IIIb polyglandular autoimmune disease (PGA) [18,44,45]. In patients with AITD, one third has AAG, which is diagnosed also in young patients [18].

In the general population, there is an age-related increase in the prevalence of PCA, from 2.5% in the third decade to 12% in the eighth decade [15,16]. In DM1 patients, PCAs are found in 10–15% of the children and in 15–25% of the adults [18,19,46–48]. The respective prevalence of AAG and PA in the general population are 2% and 0.15–1% [16,17], compared with 5–10% and 2.6–4%, respectively, in DM1

patients [21]. Iron deficiency anemia is present in 20–40% of patients with AAG [2], whereas PA can be diagnosed in up to 15–25% of the patients [47].

2.3. Patients with *Helicobacter pylori* infection

Although HP itself is not directly carcinogenic, AG is the single most potent risk factor of GC [48-50]. In some 5-10% of the patients with HP infection, mucosal atrophy is moderate or severe, and the risk of GC increases in parallel with the severity of AG. Compared with healthy stomach, the risk is 2-5 times higher in those with only chronic HP gastritis but up to **90-fold** in patients **with severe AG** both in the corpus and antrum (pan-gastritis; AGpan) [48-51].

It is estimated that HP-infection is involved in >90% of all GC cases that develop through the "Correa cascade", from intermediate steps of AG, IM, and dysplasia. It is important to recall that this cascade can often (but not invariably) be interrupted by appropriate early treatment of HP infection [48-53]. In addition to being the key risk factor of GC, HP infection also plays a causative role in the development of **peptic ulcer disease** [49,50]. Similarly, both AG and HP can be responsible for the symptoms known as dyspepsia; organic or functional [54]. Debate still continues on the value of systematic HP eradication in relieving the dyspeptic symptoms [50,51,54].

3. SUBJECTS AT RISK FOR INCREASED EXPOSURE TO ACETALDEHYDE

3.1. Cigarette smokers, alcohol drinkers

Another group of people at increased risk of GC are all those who are subjected to increased exposure to carcinogenic acetaldehyde [36-38]. These can be roughly divided into two groups: 1) those with **acid-free stomach** irrespective of its cause, and 2) those exposed to acetaldehyde due to specific reasons. Accordingly, acid-free stomach due to any cause (AG, AAG, **PPI-users**) predisposes the subject to acetaldehyde exposure and thus increases the risk of developing GC and esophageal cancer [36-38]. Acetaldehyde is the major carcinogenic substance in cigarette smoke, predisposing **cigarette smokers** to acetaldehyde exposure in oral cavity and the upper gastrointestinal tract [36-38,55,56]. The same applies to **alcohol intake**, because acetaldehyde is the first metabolite of alcohol, also produced in the stomach endogenously from ethanol, e.g. by local microbial or mucosal oxidation of ethanol to acetaldehyde [36-38,57,58].

3.2. ALDH2 mutation

Another well-known condition that increases the risk of acetaldehyde exposure is a point mutation in ALDH2-gene, resulting in deficient activity of the main acetaldehyde-metabolizing enzyme (ALDH2) [59,60]. When drinking alcohol, the upper digestive tract mucosa of ALDH2-deficients is exposed via saliva to about 2-times and via gastric juice, up to 5–6 times higher acetaldehyde concentrations than in persons with active ALDH2-

enzyme (58-61). Parallel to increased local acetaldehyde exposure, the risk of ALDH2-deficient alcohol drinkers for oral, pharyngeal, esophageal and gastric cancer is many-fold compared to alcohol drinking ALDH2-actives. Thus, ALDH2-deficiency provides a unique human cancer model for local acetaldehyde exposure in the upper digestive tract.

3.3. Chronic users of PPI medication

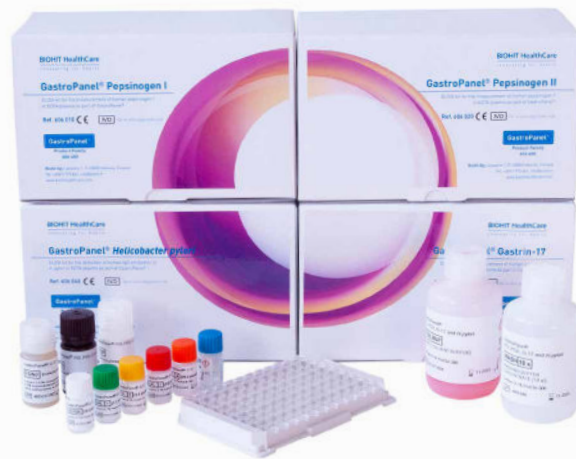Another risk group are the chronic users of PPI-medication. Two recently published meta-analyses suggest that the use of acid-suppressive (PPI) drugs is associated with an increased risk of GC (62,63). A denominator in common with AG is **acetaldehyde** endogenously formed from ethanol (36-38,55-58). An acid-free stomach secondary to either AG or PPI-treatment is **colonized by oral microbes**, which effectively **produce acetaldehyde** from ingested alcohol via their ADH enzymes. This was convincingly demonstrated in recent experiments, where PPI-treatment for 7 days significantly increased gastric juice acetaldehyde levels in ALDH2-active subjects after intra-gastric infusion of alcohol. Importantly, **the highest** gastric juice **acetaldehyde concentrations** were measured in **PPI-treated**, ALDH2-deficient subjects (61).

4. MONITORING THE PATIENTS WITH AG/AAG AND THOSE WITH INCREASED EXPOSURE TO ACETALDEHYDE

So far, it has been argued whether patients with AG/AAG and PA should be placed under a surveillance program with regular gastroscopies, including multiple gastric biopsies (21,24). In these subjects, the risk of developing GC is real. Nevertheless, in many clinics, endoscopy with biopsies remains the gold standard diagnostic tool, disclosing HP infection, AG, IM or dysplasia (48,49). However, this invasive method is uncomfortable, distressing and quite costly, emphasizing the **need for rapid, reliable and inexpensive non-invasive tests** for screening and monitoring these patients (64,65).

As a response to this unmet need, a Finnish biotechnology company Biohit Oyj (Helsinki) developed a simple blood test based on a panel of serum pepsinogen I (PGI) and II (PGII), gastrin-17 (G-17) and HP IgG antibodies (IgG-HP) using ELISA technique (GastroPanel® test), proposed as the first-line diagnostic test for dyspeptic symptoms (66-68). According to a recent meta-analysis, **serum PGs are not suitable for screening of GC, but extremely useful for disclosing the patients at risk for GC** (69), as also recommended by an authoritative international group of experts (70).

The GastroPanel® test is based on combined analysis of PG-I, PG-II, amidated G-17 and HP-antibodies, designed to give information on both the structure and function of the stomach mucosa. Most importantly, this panel gives accurate estimates of the capacity of the corpus and antrum mucosa to secrete acid and G-17, respectively, as



well as of important gastric pathologies like inflammation, grade and topography of AG (66-68,71-73). Normal plasma levels of these biomarkers indicate that the stomach mucosa has normal structure and function, whereas the abnormal levels are signs of a non-healthy stomach, reflecting the disturbances in the feedback mechanisms between the acid output, PGs and G-17 (40-43,74).

4.1. GastroPanel® test

GastroPanel® test has been on the market for several years by now, and during that time, it has been validated in clinical studies worldwide (75-78). Due to the inherent characteristics of the natural history of AG/AAG, the PGI values (and PGI/PGII ratio) remain within normal range as long as AG of the corpus (AGC) is graded only mild. However, mild AG/AAG is a poorly reproducible diagnostic category and should never be used as the study endpoint in calculating the performance indicators of the PGI, PGI/PGII (77-79). The correct way of calculating the predictive indicators of PGI and PGI/PGII ratio for AGC is to use the combined **moderate/severe AG** as the study endpoint (40,80).

To provide an unbiased estimate of the accumulated evidence, two recent meta-analysis have been performed with a systematic review of all studies published on GastroPanel® test since its introduction in the early 2000's (40,80). Both meta-analyses gave practically similar results. In both analyses, the pooled sensitivity of GastroPanel® in detection of AG exceeded 70% and the pooled specificity was close to 95% (40,80). Both meta-analyses concluded that GastroPanel® test appears to be a reliable tool for the diagnosis of AG, and applicable for both screening of the subjects or populations at high-risk of GC (40,80).

4.2. Interpretation of the GastroPanel® results

GastroPanel® is optimized for use in context with the USS classification of gastritis (53). Both the USS and the GastroSoft® software use five diagnostic categories to classify the biopsies and the GastroPanel® results, respectively. These include: 1) normal mucosa, 2) superficial (HP) gastritis, 3) AGA, 4) AGC, and 5) AG in both antrum and corpus (AGpan) (53). In addition to these five categories related to stomach morphology, **three**

other marker profiles are produced by GastroSoft®, being specific for **functional disturbances** in acid output (40-43).

The interpretation of GastroPanel® test with GastroSoft® has been detailed in a series of recent reports (40-43,81-83). These reviews include detailed descriptions of the eight diagnostic marker profiles that are possible to obtain with GastroPanel® test (40-43,81-83). These distinct profiles include: 1) normal profile; 2) high acid output; 3) low acid output due to **PPI-medication**; 4) superficial (non-atrophic), HP-associated gastritis, with 3 options (active HP-infection; successful HP eradication; failed HP eradication); 5) atrophic gastritis of the corpus (AGC); 6) atrophic gastritis of the antrum (AGA); 7) atrophic gastritis of the antrum and corpus (AGpan); and 8) panel profile in linked with the PPI use (40-43,81-83).

5. ACETIUM® CAPSULE FOR PROTECTION OF ACID-FREE STOMACH

The carcinogenic agent in common to both HP and AG/AAG is acetaldehyde, determined as Group I human carcinogen by IARC in 2009 (36). Apart from HP itself which is capable of synthesizing acetaldehyde, the other bacteria colonizing in acid-free stomach of patients with AG, are an abundant source of this carcinogenic substance. Acid-free stomach due to any cause (AG, AAG, PPI) predisposes the subject to acetaldehyde exposure and thus increases the risk of GC and esophageal cancer (36-38). The special groups of patients at increased risk of the carcinogenic exposure to acetaldehyde are those listed above (section 3). These high-risk subjects should be closely monitored for GC precursor lesions (AG, IM) by GastroPanel® and/or gastroscopy (35). Preferably, these patients should also be instituted on regular stomach protection by Acetium® capsules, as repeatedly pointed out (35). The theoretical basis and rationale for this practice are summarized here in brief (35).

5.1. Acetium® capsule effectively eliminates acetaldehyde in the stomach

L-cysteine is a non-essential amino acid, which was shown (in 1975) to be capable of eliminating the toxicity of acetaldehyde by reacting covalently with it to form a stable 2-methylthiazolidine-4-carboxylic acid (MTCA)(84). MTCA is a stable and inert compound that is eliminated from the body mainly through feces. This principle was used by Biohit in its recent innovation of Acetium® Capsule, which contains 100mg L-cysteine. The novelty of this new formulation of slow-release L-cysteine is based on the local elimination of carcinogenic acetaldehyde in the stomach (35). After the proof-of-concept experiments in the laboratory, the efficacy of this Acetium® formulation has been conclusively demonstrated in three carefully controlled clinical studies in Finland (58), Sweden (85), and Japan (61).

5.1.1. Elimination of acetaldehyde in subjects with acid-free stomach

In a placebo-controlled study, slow-release L-cysteine capsules effectively eliminated ethanol-derived

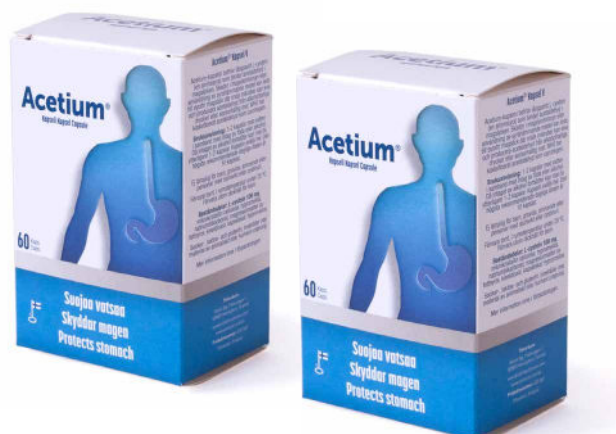acetaldehyde in the gastric juice of patients with AGC (58). Seven volunteers with acid-free AGC were given either slow-release L-cysteine or placebo capsules in a double-blinded randomized trial. Five-milliliter samples of gastric contents were aspirated at 5-minute intervals (58). During the follow-up, the mean acetaldehyde level in gastric juice was 2.6-times higher with placebo than with L-cysteine ($p=0.005$)(58). These results confirm that Acetium® Capsule effectively decrease acetaldehyde concentration in **an acid-free stomach** during alcohol exposure.

5.1.2. Elimination of acetaldehyde in patients with AG

In the second study, patients with AGC received 15% ethanol (0.3g/kg) through a nasogastric tube on two separate days, accompanied by randomized Acetium® Capsule (2 x 100mg) or placebo (85). After intra-gastric infusion of 15% ethanol with placebo, gastric juice acetaldehyde levels increased from zero to mean 36 μ M (peak) and remained elevated up to 100 min. Slow-release L-cysteine decreased gastric juice acetaldehyde by a mean of 68% (max. 87% at 60 min) and the decline persisted for up to two hours (85). Furthermore, the peak gastric juice MTCA level (233 μ M) was seen at 80 min and gastric juice MTCA remained elevated for up to 180 min (36 μ M at 180 min). These data implicate that i) an exposure of gastric mucosa to acetaldehyde is decreased by a mean of 68% ($p<0.0001$) with slow-release L-cysteine capsule, and this effect continues for at least two hours; ii) MTCA remains stable in the gastric juice for up to three hours (85).

5.1.3. Acetaldehyde elimination, ALDH2 mutation and PPI-treatment

The third clinical trial confirmed that slow-release Acetium® Capsule (2 x 100 mg) reduced markedly the gastric juice acetaldehyde levels also **in PPI-treated** individuals with either active or deficient ALDH2 enzyme (61). This study was conducted in Japan, showing that acetaldehyde eliminating capacity of slow-release L-cysteine was effective even after a moderate dose (0.5 g/kg, 3 doses) of alcohol and persisted for 2 hours. This acetaldehyde-eliminating effect of L-cysteine persisted almost 120 minutes. Quantitatively, L-cysteine resulted in a mean of 67% (3-fold) decrease in gastric juice acetaldehyde ($p=0.001$)(61).



6. CONCLUSIONS

6.1. GastroPanel® biomarker test for monitoring of the high-risk subjects

GastroPanel® is the first non-invasive diagnostic tool based on physiology of three stomach-specific biomarkers of both health and disease. The panel also includes testing for HP infection, the key etiological factor in pathogenesis of peptic ulcer and GC. In the current test version (the Unified GastroPanel®), all 4 biomarkers are being processed under similar conditions. GastroPanel® will be soon available in the quick test version (GPQT) as well, particularly suitable for the POC (point-of-care) testing at doctors' offices with restricted facilities for blood sample processing. In GastroPanel®, the HP antibody measurement is complemented by the other three biomarkers (PGI, PGII, G-17) which are sensitive indicators of mucosal inflammation. (www.gastropanel.com). This 4-marker panel makes GastroPanel® **the most comprehensive HP test**, devoid of the known shortcomings (false negative and false positive results) of the conventional HP tests (81-83).

The non-invasive GastroPanel® test is particularly suitable for monitoring of i) all patients at increased risk of GC, irrespective whether due to AG caused by HP-infection or autoimmune disease, as well as of ii) all those who are subjected to increased exposure to carcinogenic acetaldehyde due to specific reasons (**acid-free stomach, smokers, alcohol intake, ALDH2 mutation, chronic PPI users**)(35).

6.2. Acetium® Capsule for protection of the stomach against carcinogenic acetaldehyde

Acetium® Capsule is a unique medical device designed for elimination of carcinogenic acetaldehyde in the stomach. (www.acetium.com). A regular use of this device is indicated for all those who have acid-free stomach, irrespective of its cause. This formulation effectively protects the stomach against the exposure to acetaldehyde, classified as Group I carcinogen by IARC (36). The efficacy of Acetium® Capsule in acetaldehyde elimination has been documented in three placebo-controlled clinical trials (58,61,85). In all studies, slow-release L-cysteine effectively (by 60-80%) eliminated acetaldehyde in patients with acid-free stomach caused by either AG or PPI-treatment, similarly in individuals with active or deficient ALDH2 enzyme. This capacity to eliminate acetaldehyde persisted for up to three hours after ingestion of two Acetium® Capsules (58,61,85).

It is recommended that this special slow-release L-cysteine formulation, devoid of any systemic side effects, should be used for long-term protection of the stomach mucosa against the effects of acetaldehyde **by all those who are over-exposed to this carcinogenic substance because of an acid-free stomach** (35,36-38,58,61,85).



REFERENCES

1. Varis K, Isokoski M. Screening of type A gastritis. *Ann Clin Res* 1981;13:133-138.
2. Telaranta-Keerie A, Kara R, Paloheimo L, Härkönen M, Sipponen P. Prevalence of undiagnosed advanced atrophic corpus gastritis in Finland: an observational study among 4,256 volunteers without specific complaints. *Scand J Gastroenterol* 2010;45:1036-1041.
3. Sipponen P, Graham D. Importance of atrophic gastritis in diagnostics and prevention of gastric cancer: application of plasma biomarkers. *Scand J Gastroenterol* 2007;42:2-10.
4. Malfertheiner P, Sipponen P, Naumann M ym. Lejondal H. pylori-Gastric Cancer Task Force. Helicobacter pylori eradication has the potential to prevent gastric cancer: a state-of-the-art critique. *Am J Gastroenterol* 2005;100:2100-2115.
5. Benberin V, Bektayeva R, Karabayeva R, Lebedev A, Akemeyeva K, Paloheimo L, Syrjänen K. Prevalence of H.pylori infection and atrophic gastritis among symptomatic and dyspeptic adults in Kazakhstan. A Hospital-Based screening with a panel of serum biomarkers. *Anticancer Res* 2013;33:4595-4602.
6. International Agency for Research on Cancer, World Health Organization. Schistosomes, liver flukes and Helicobacter pylori. IARC working group on the evaluation of carcinogenic risks to human. *Monogr Eval Carcinog Risks Hum* 1994;61:218-220.
7. Correa P, Haenszel W, Cuello C, Zavala D, Fontham E, Zarama G, et al. Gastric precancerous process in a high risk population: cohort follow-up. *Cancer Res* 1990;50:4737-4740.
8. Filipe MI, Munoz N, Matko I, Kato I, Pompe-Kirn V, Jutersek A, et al. Intestinal metaplasia types and the risk of gastric cancer: a cohort study in Slovenia. *Int J Cancer* 1994;57:324-329.
9. Uemura N, Okamoto S, Yamamoto S, Matsumura N, Yamaguchi S, Yamakido M, et al. Helicobacter pylori infection and the development of gastric cancer. *N Engl J Med* 2001;345:829-832.
10. Sipponen P, Kekki M, Haapakoski J, Ihamäki T, Siurala M. Gastric cancer risk in chronic atrophic gastritis: statistical calculations of cross-sectional data. *Int J Cancer* 1985;35:173-177.
11. Ohata H, Kitauchi S, Yoshimura N, Mugitani K, Iwane M, Nakamura H, et al. Progression of chronic atrophic gastritis associated with Helicobacter pylori infection increases risk of gastric cancer. *Int J Cancer* 2004;109:138-143.
12. Varis K, Sipponen P, Laxen F, Samloff IM, Huttunen JK, Taylor PR, and The Helsinki Gastritis Study Group. Implications of serum pepsinogen I in early endoscopic diagnosis of gastric cancer and dysplasia. *Scand J Gastroenterol* 2000;35:950-956.
13. Sipponen P, Laxén F, Huotari K, Härkönen M. Prevalence of low vitamin B12 and high homocysteine in serum in an elderly male population: association with atrophic gastritis and Helicobacter pylori infection. *Scand J Gastroenterol* 2003;38:1209-1216
14. Sipponen P, Härkönen M. Hypochlorhydric stomach: a risk condition for calcium malabsorption and osteoporosis? *Scand J Gastroenterol* 2010;45:133-138.
15. Whittingham S, Mackay IR. Pernicious anemia and gastric atrophy. In: Rose NR, Mackay IR, eds. *The autoimmune diseases*. New York: Academic Press;1985;243-266.
16. Jacobson DL, Gange SJ, Rose NR, Graham NM. Epidemiology and estimated population burden of selected autoimmune diseases in the United States. *Clin Immunol Immunopathol* 1997;84:223-243.
17. Carmel R. Prevalence of undiagnosed pernicious anemia in the elderly. *Arch Intern Med* 1996;156:1097-1100.
18. Centanni M, Marignani M, Gargano L, Corleto VD, Casini A, Delle Fave G, Andreoli M, Annibale B. Atrophic body gastritis in patients with autoimmune thyroid disease. An underdiagnosed association. *Arch Intern Med* 1999;159:1726-1730.
19. Irvine WJ, Scarth L, Clarke BF, Cullen R, Duncan LJP. Thyroid and gastric autoimmunity in patients with diabetes mellitus. *Lancet* 1970;2:163-168.
20. Riley WJ, Toskes PP, Maclaren NK, Silverstein J. Predictive value of gastric parietal cell autoantibodies as a marker for gastric and hematologic abnormalities associated with insulin dependent diabetes. *Diabetes* 1982;31:1051-1055.
21. De Block CEM, De Leeuw IH, Van Gaal LF.. Autoimmune Gastritis in Type 1 Diabetes: A Clinically Oriented Review. *J Clin Endocrinol Metab* 2008;93:363-371.
22. Strickland RG, Mackay I. A reappraisal of the nature and significance of chronic atrophic gastritis. *Am J Dig Dis* 1973;18:426-440.
23. Marignani M, Delle Fave G, Mecarocci S, Bordi C, Angeletti S, D'Ambra G, Aprile MMR, Corleto VD, Monarca B, Annibale B. High prevalence of atrophic body gastritis in patients with unexplained microcytic and macrocytic anemia. *Am J Gastroenterol* 1999;94:766-772.
24. De Block CE, Van Campenhout CM, De Leeuw IH, Keenoy BM, Martin M, Van Hoof V, Van Gaal LF. Soluble transferrin receptor level: a new marker of iron deficiency anemia, a common manifestation of gastric autoimmunity in type 1 diabetes. *Diabetes Care* 2000;23:1384-1388.
25. Collins AB, Pawlak R. Prevalence of vitamin B-12 deficiency among patients with thyroid dysfunction. *Asia Pac J Clin Nutr* 2016;25:221-226. doi: 10.6133/apjcn.2016.25.2.22.
26. Kokkola A, Sjöblom SM, Haapiainen R, Sipponen P, Puolakainen P, Järvinen H. The risk of gastric carcinoma and carcinoid tumours in patients with pernicious anaemia: a prospective follow-up study. *Scand J Gastroenterol* 1998;33:88-92.
27. Addison T. Anaemia: disease of the suprarenal capsules. *London Med Gaz*1849; 8:517-518.
28. Flint A. A clinical lecture on anaemia, delivered at the Long Island College Hospital. *American Medical Times* 1860;1:181-186.
29. Castle WB. Development of knowledge concerning the gastric intrinsic factor and its relation to pernicious anemia. *N Engl J Med* 1953;249:603-614.
30. Schwartz M. Intrinsic factor antibody in serum from patients with pernicious anaemia. *Lancet* 1960;2:1263-1267.
31. Irvine WJ, Davies SH, Delamore IW, Williams AW. Immunological relationship between pernicious anemia and thyroid disease. *Br J Med* 1962;2:454-456.
32. Irvine W. Immunologic aspects of pernicious anemia. *N Engl J Med* 1965;273:432-438.

33. Stabler S. Vitamin B12 deficiency. *N Engl J Med* 2013;368:149-160.
34. Bolander-Gouaille C. Focus on Homocysteine and the Vitamins involved in its Metabolism. Berlin: Springer Verlag. 2002
35. Syrjänen K. Serum biomarker panel (GastroPanel®) and slow-release L-cysteine (Acetium® Capsule): Rationale for the primary prevention of gastric cancer. *EC Gastroenterol Digest Syst* 2017;3(6):172-192.
36. Secretan B, Straif K, Baan R, Grosse Y, El Ghissassi F, Bouvard V, Benbrahim-Tallaa L, Guha N, Freeman C, Galichet L, Cogliano V. WHO International Agency for Research on Cancer Monograph Working Group. A review of human carcinogens - Part E: tobacco, areca nut, alcohol, coal smoke, and salted fish. *Lancet Oncol* 2009;10:1033-1034.
37. Salaspuro M. Acetaldehyde as a common denominator and cumulative carcinogen in digestive tract cancers. *Scand J Gastroenterol* 2009;24:1-15.
38. Salaspuro V, Salaspuro M. Synergistic effect of alcohol drinking and smoking on in vivo acetaldehyde concentration in saliva. *Int J Cancer* 2004;111:480-486.
39. Aine R, Kahar E, Aitokari K, Salminen J, Eklund C, Paloheimo L, Peetsalu A, Syrjänen K. Atrophic gastritis (AG) and its clinical sequels among elderly people in Finland and Estonia. A comparative study using GastroPanel and B12-vitamin testing of the residents in assisted-housing facilities. *J Aging Res Clin Pract* 2016;5:194-202.
40. Syrjänen K. A Panel of serum biomarkers (GastroPanel®) in non-invasive diagnosis of atrophic gastritis. Systematic review and meta-analysis. *Anticancer Res* 2016;36:5133-5144.
41. Ebule IA, Djune Fokou AK, Sitedjeya Moko IL, Tanni B, Heugueu C, Longdoh AN, Noah Noah D, Okomo Assoumou MC, Paloheimo L, Njoya O, Syrjänen K. Prevalence of *H. pylori* infection and atrophic gastritis among dyspeptic subjects in Cameroon using a panel of serum biomarkers (PGI, PGII, G-17, HplgG). *Sch J Appl Med Sci* 2017;5(4A):1230-1239.
42. Syrjänen K. Role of serological biomarker testing (GastroPanel®) in diagnosis of symptomatic dyspepsia and in screening of the risks of stomach cancer. *EC Gastroenterol Digest Syst* 2017;1(6):209-222.
43. Syrjänen K. Serological biomarker panel (GastroPanel®): A test for non-invasive diagnosis of dyspeptic symptoms and for comprehensive detection of *Helicobacter pylori* infection. *Biomark J* 2017;3:1-10.
44. Neufelt M, Blizzard RM. Polyglandular autoimmune disease. In: Pinchera A (Ed). *Autoimmune Aspects of Endocrine Disorders*. New York, Academic Press. 1980;357-365.
45. Venerito M, Radünz M, Reschke K, Reinhold D, Frauenschläger K, Jechorek D, Di Mario F, Malferteiner P. Autoimmune gastritis in autoimmune thyroid disease. *Aliment Pharmacol Ther* 2015;41:686-693.
46. Maclaren NK, Riley WJ. Thyroid, gastric, and adrenal autoimmunities associated with insulin-dependent diabetes mellitus. *Diabetes Care* 1985;8(Suppl1):34-38.
47. Betterle C, Zanette F, Pedini B, Presoto F, Rapp LB, Monciotto CM, Rigon F. Clinical and subclinical organ-specific autoimmune manifestations in type 1 (insulin-dependent) diabetic patients and their first-degree relatives. *Diabetologia* 1984;26:431-436.
48. Landin-Olsson M, Karlsson FA, Lernmark A, Sundkvist G. Islet cell and thyrogastic antibodies in 633 consecutive 15- to 34-yr-old patients in the diabetes incidence study in Sweden. *Diabetes* 1992;41:1022-1027.
47. Toh BH, Alderuccio F. Pernicious anaemia. *Autoimmunity* 2004;37:357-361.
48. Correa P. Human gastric carcinogenesis: a multistep and multifactorial process. First American Cancer Society Award Lecture on Cancer Epidemiology and Prevention. *Cancer Res* 1992;52:6735-49.
49. Carpenter C, Patalas E. Case records of the Massachusetts General Hospital [Case 40-2000]: a 38-year-old woman with gastric adenocarcinoma. *N Engl J Med* 2000;343:1951-1958.
50. Malferteiner P, Sipponen P, Naumann M. H. pylori-Gastric Cancer Task Force. *Helicobacter pylori* eradication has the potential to prevent gastric cancer: a state-of-the-art critique. *Am J Gastroenterol* 2005;100:2100-2115.
51. Malferteiner P, Megraud F, O'Morain CA, Gisbert JP, Kuipers EJ, Axon AT, Bazzoli F, Gasbarrini A, Atherton J, Graham DY, Hunt R, Moayyedi P, Rokkas T, Rugge M, Selgrad M, Suerbaum S, Sugano K, El-Omar EM. on behalf of the European *Helicobacter* and Microbiota Study Group and Consensus panel. Management of *Helicobacter pylori* infection—the Maastricht V/Florence Consensus Report. *Gut* 2017;66:6-30. doi:10.1136/gutjnl-2016-312288.
52. Varis K, Sipponen P, Laxen F. The Helsinki Gastritis Study Group. Implications of serum pepsinogen I in early endoscopic diagnosis of gastric cancer and dysplasia. *Scand J Gastroenterol* 2000;35:950-956.
53. Sipponen P, Price AB. The Sydney system for classification of gastritis 20 years ago. *J Gastroenterol Hepatol* 2011;26:Suppl. 1;31-34.
54. Moayyedi P, Talley NJ, Fennerty MB, Vakil N. Can the clinical history distinguish between organic and functional dyspepsia? *JAMA* 2006;295:1566-1576.
55. Haussman HJ. Use of hazard indices for a theoretical evaluation of cigarette smoke composition. *Chem Res Toxicol* 2012;25:794-810.
56. Cao J, Belluzzi JD, Loughlin SE, Keyler DE, Pentel PR, Leslie FM. Acetaldehyde, a major constituent of tobacco smoke, enhances behavioral, endocrine, and neuronal responses to nicotine in adolescent and adult rats. *Neuropsychopharmacol* 2007;32:2025-2035.
57. Seitz HK, Stickel F. Acetaldehyde as an underestimated risk factor for cancer development: role of genetics in ethanol metabolism. *Genes Nutr* 2010;5:121-128.
58. Linderborg K, Marvola T, Marvola M, Salaspuro M, Färkkilä M, Väkeväinen S. Reducing carcinogenic acetaldehyde exposure in the achlorhydric stomach with cysteine. *Alcohol Clin Exp Res* 2011;35:516-522.
59. Lachenmeier DW, Salaspuro M. ALDH2-deficiency as genetic epidemiologic and biochemical model for the carcinogenicity of acetaldehyde. *Regul Toxicol Pharmacol*. 2017;86:128-136.
60. Salaspuro M. Acetaldehyde: a cumulative carcinogen in humans. *Addiction*. 2009;104:551-553.
61. Maejima R, Iijima K, Kaihovaara P, Hatta W, Koike T, Imatani A, Shimosegawa T, Salaspuro M. Effects of ALDH2 genotype, PPI treatment and L-cysteine on carcinogenic acetaldehyde in gastric juice and saliva after intra-gastric alcohol administration. *PLoS One*. 2015;10:e0120397.

62. Ahn JS, Eom CS, Jeon CY, Park SM. Acid suppressive drugs and gastric cancer: A meta-analysis of observational studies. *World J Gastroenterol* 2013;19:2560-2568.
63. Tran-Duy A, Spaetgens B, Hoes AW, de Wit NJ, Stehouwer CD. Use of Proton Pump Inhibitors and Risks of Fundic Gland Polyps and Gastric Cancer: Systematic Review and Meta-analysis. *Clin Gastroenterol Hepatol*. 2016;14:1706-1719.
64. Lomba-Viana R, Dinis-Ribeiro M, Fonseca F, Vieira AS, Bento MJ, Lomba-Viana H. Serum pepsinogen test for early detection of gastric cancer in a European country. *Eur J Gastroenterol Hepatol* 2012;24:37-41.
65. Bornschein J, Selgrad M, Wex T, Kuester D, Malfertheiner P. Serological assessment of gastric mucosal atrophy in gastric cancer. *BMC Gastroenterol* 2012;12:10. doi: 10.1186/1471-230X-12-10.
66. Korstanje A, den Hartog G, Biemond I, Lamers CB. The serological gastric biopsy: a non-endoscopic diagnostic approach in management of the dyspeptic patient: significance for primary care based on a survey of the literature. *Scand J Gastroenterol Suppl* 2002;236:22-26.
67. Oksanen A, Sipponen P, Miettinen A, Sarna S, Rautelin H. Evaluation of blood tests to normal gastric mucosa. *Scand J Gastroenterol* 2000;35:791-795.
68. Varis K, Sipponen P, Laxen F, Samloff IM, Huttunen JK, Taylor PR, The Helsinki Gastritis Study Group. Implications of serum pepsinogen I in early endoscopic diagnosis of gastric cancer and dysplasia. *Scand J Gastroenterol* 2000;35:950-956.
69. Miki K. Gastric cancer screening using the serum pepsinogen test method. *Gastric Cancer* 2006;9:245-253.
70. Agréus L, Kuipers EJ, Kupcinskas L, Malfertheiner P, Di Mario F, Leja M, Mahachai V, Yaron N, van Oijen M, Perez Perez G, Rugge M, Ronkainen J, Salaspuro M, Sipponen P, Sugano K, Sung J. Rationale in diagnosis and screening of atrophic gastritis with stomach-specific plasma biomarkers. *Scand J Gastroenterol* 2012;47:136-147.
71. Varis K, Isokoski M. Screening of type A gastritis. *Ann Clin Res* 1981;13:133-138.
72. Sipponen P, Valle J, Varis K, Kekki M, Ihamäki T, Siurala M. Fasting levels of serum gastrin in different functional and morphologic states of the antrofundal mucosa. An analysis of 860 subjects. *Scand J Gastroenterol* 1990;25:513-519.
73. Varis K, Kekki M, Härkönen M, Sipponen P, Samloff IM. Serum pepsinogen I and serum gastrin in the screening of atrophic pangastritis with high risk of gastric cancer. *Scand J Gastroenterol* 1991;186:117-123.
74. Sipponen P, Ranta P, Helske T, Kääriäinen I, Mäki T, Linnala A. Serum levels of amidated gastrin-17 and pepsinogen I in atrophic gastritis: an observational case-control study. *Scand J Gastroenterol* 2002;37:785-791.
75. Storskrubb T, Aro P, Ronkainen J, Sipponen P, Nyhlin H, Talley NJ. Serum biomarkers provide an accurate method for diagnosis of atrophic gastritis in a general population: the Kalixanda study. *Scand J Gastroenterol* 2008;43:1448-1455.
76. Telaranta-Keerie A, Kara R, Paloheimo L, Härkönen M, Sipponen P. Prevalence of undiagnosed advanced atrophic corpus gastritis in Finland: an observational study among 4,256 volunteers without specific complaints. *Scand J Gastroenterol* 2010;45:1036-1041.
77. Väänänen H, Vauhkonen M, Helske T. Non-endoscopic diagnosis of atrophic gastritis with a blood test. Correlation between gastric histology and serum levels of gastrin-17 and pepsinogen I: a multicentre study. *Eur J Gastroenterol Hepatol* 2003;15:885-891.
78. Kurilovich SA, Belkovets AV, Reshetnikov OV, Openko TG, Malyutina SK, Ragino YI, Scherbakova LV, Leja M, Paloheimo L, Syrjänen K, Voevoda MI. Stomach-specific biomarkers (GastroPanel) can predict the development of gastric cancer in Caucasian population: A longitudinal nested case-control study in Siberia. *Anticancer Res* 2016;36:247-254.
79. Syrjänen KJ, Sipponen P, Härkönen M, Peetsalu A, Korpela S. Accuracy of GastroPanel testing in detection of atrophic gastritis. *Eur J Gastroenterol Hepatol* 2015;27:102-104.
80. Zagari RM, Rabitti S, Greenwood DC, Eusebi LH, Vestito A, Bazzoli F. Systematic review with meta-analysis: diagnostic performance of the combination of pepsinogen, gastrin-17 and anti-*Helicobacter pylori* antibodies serum assays for the diagnosis of atrophic gastritis. *Aliment Pharmacol Ther* 2017;1-11.
81. Syrjänen K, Eronen K. Serological testing in management of dyspeptic patients and in screening of gastric cancer risks. *J Gastrointest Disord Liver Funct* 2016;2[3]:1-5.
82. Syrjänen K. Caveats in diagnosis of *Helicobacter pylori* infection can be avoided by a panel of serum biomarkers (GastroPanel®). An Invited Editorial. *J Carcinog Mutagen* 2017;7[6]:e123. .
83. Syrjänen K. False negative and false positive results in diagnosis of *Helicobacter pylori* infections can be avoided by a panel of serum biomarkers (GastroPanel®). *M J Gast*. 2017;1[1]:007-014.
84. Sprince H, Parker CM, Smith GG, Gonzales LJ. Protective action of ascorbic acid and sulfur compounds against acetaldehyde toxicity: implications in alcoholism and smoking. *Agents Actions* 1975;5:164-173.
85. Hellström PM, Hendolin P, Kaihovaara P, Kronberg L, Meierjohann A, Millerhov A, Paloheimo L, Sundelin H, Syrjänen K, Webb D-L, Salaspuro M. Slow-release L-cysteine capsule prevents gastric mucosa exposure to carcinogenic acetaldehyde: results of a randomised single-blinded, cross-over study of *Helicobacter*-associated atrophic gastritis. *Scand J Gastroenterol* 2016;52:230-237.



BIOHIT HealthCare

Innovating for Health

Laippatie 1
00880 Helsinki
Finland
Tel. +358 9 773 861

<https://www.biohithealthcare.com>
<https://www.gastropanel.com>
<https://www.acetium.com>