

**State of the art  
GastroPanel and  
Acetium innovations  
for the unmet need**

# State of the art GastroPanel and Acetium innovations for the unmet need

## **Innovations for the development of safe, ethical and cost-effective treatment of dyspepsia and *Helicobacter pylori* infection.**

Gastrointestinal disorders are a growing global medical, ethical and economic problem. They are among the most common types of complaints made to primary care physicians worldwide and are associated with a substantial healthcare and economic burden. Despite being one of the world's largest therapeutic areas and presenting huge burdens on healthcare systems and economies globally, many of the diseases of the gastrointestinal tract are still poorly understood, and treatment (diagnosis & therapy) options are far from optimal, leaving many patients dissatisfied with their current treatment and others left without effective and safe treatment (43).

Without a diagnosis, many resort to risky self-treatments for dyspepsia and heartburn. The aging of the population increases the occurrence of serious illnesses, such as gastric, oesophageal and colorectal cancer, and conditions associated with vitamin B12 and trace element deficiencies. This places a rapidly growing burden on health and well-being and affects working capacity and ability to prolong working careers. Outdated guidelines and

tests, such as the 13C urea breath test (UBT) and stool antigen test, that may even lead to treatment errors should be replaced with modern, reliable tests and guidelines for dyspepsia and *H. pylori* infection in primary health care (Figure, Table, Appendix).

**The state of the art, safe and cost-effective GastroPanel examination does not involve any of the serious medical problems presented as follows.** The 13C urea breath test (UBT), stool antigen test and antibody tests do not detect atrophic gastritis which is caused by *H. pylori* infection or an autoimmune disease. The diagnosis of in most cases asymptomatic atrophic gastritis is important because of the associated risks, including gastric and oesophageal cancer and malabsorption of vitamin B12, iron, magnesium, calcium and some drugs. Calcium deficiency causes osteoporosis, and vitamin B12 deficiency can cause Alzheimer's disease, dementia, depression and polyneuropathy, as well as high homocysteine content in the body, which in turn is thought to be an independent risk factor for atherosclerosis, heart attacks and strokes.

The absorption of dipyridamole, some iron products and antifungals (fluconazole, itraconazole), thyroxine and atazanavir is considerably impaired in an anacidic stomach. Atrophic gastritis in the gastric corpus and PPI therapy cause anacidity (aclorhydria) of the stomach. The risk of pneumonias and, in senior citizens, even the risk of fatal intes-

tinal infections (such as giardiasis, malaria, *Clostridium difficile* and *E. coli* EHEC) has been shown to increase significantly in an anacidic stomach. *H. pylori* gastritis may also develop into antral atrophic gastritis, which increases the risk of peptic ulcer disease and gastric cancer. If both antrum and corpus mucosa are atrophic, this condition is the highest risk for gastric cancer known to date.

Furthermore, none of the aforementioned three *H. pylori* tests provides any information on excessive gastric acid secretion, which in patients with gastro-oesophageal reflux disease may cause complications of this disease. Such complications are often asymptomatic and include ulcerative oesophagitis and Barrett's oesophagus, which may lead to oesophageal cancer if left untreated. In addition, the 13C urea breath test and stool antigen test may give up to 50 % false negative results if the patient has a) atrophic gastritis b) MALT lymphoma or c) bleeding peptic ulcer disease or d) if the patient is currently receiving antibiotics or PPIs.

Pasechnikov et al have made the following pertinent conclusions (25): *"The analysis of the literature data and results of our own research allow us to conclude that the serious medical and ethical problems of the "test and treat" strategy can be corrected simply and economically by replacing its 13C-urea breath test or stool antigen test by the GastroPanel examination. Talley et al. (2004) indicate that in many countries, such as Sweden*

and the US, the “test and treat” strategy alone is not considered sufficient. The *H. pylori* tests of the “test and treat” strategy does not find atrophic gastritis and related risks, such as gastric cancer and precancerous lesions, which should be confirmed by gastroscopy and biopsy specimen examination and would be successfully treated. Consequently, GastroPanel & gastroscopy and biopsy specimen examinations reveal patient with precancerous lesions and early stage gastric cancers, and, therefore, save people from unnecessary deaths because of gastric cancer.” (Figure and Table).

The ageing population results in an increase in serious conditions such as atrophic gastritis caused by *Helicobacter pylori* infection or autoimmune disease, gastro-oesophageal reflux disease, gastric, oesophageal- and colon cancers and peptic ulcer disease as well as the deficiency of vitamin B12, iron and calcium. Vitamin B12 deficiency may lead to dementia, depression, polyneuropathy and high homocysteine, that is thought to be an independent risk factor for atherosclerosis, heart attacks and strokes. Calcium deficiency is a growing risk factor for osteoporosis. This puts an increasingly heavy burden on public health care, people's well-being and the ability to manage longer at work and in working life. Moreover, many treatment practices are inadequate and outdated, such as the <sup>13</sup>C urea breath- and stool antigen tests used in the “test and treat strategy” for the treatment of dyspepsia and *H. pylori* infection (Table).

Approximately one third of the Finnish population has dyspeptic complaints. Dyspeptic symptoms include constant or intermittent upper abdominal pain, bloating, heartburn, belching and nausea. However, of all visits to general practitioners the proportion of dyspepsia patients is possibly as low as less than 5 percent, as people are dissatisfied with the current treatment of dyspepsia which is not widely available. Dyspeptic complaints lead to repeated examinations and the use of over-the-counter (OTC) products, such as proton pump inhibitors (PPIs) and even yoghurts for abdominal discomfort. Dyspeptic complaints, which reduce the quality of life and working ability, may have either a functional or an organic cause. Irritable bowel syndrome (benign intestinal symptoms) may be associated with functional dyspepsia, and, as much as 50 percent of dyspepsia symptoms may originate from the colon, especially in the elderly population.

### History of the GastroPanel innovation

The GastroPanel and GastroSoft innovations are based on the long Finnish research and co-work tradition into chronic gastritis and associated gastric diseases (36-41), and on the Nobel price awarded discovery of *Helicobacter pylori* and the role of this novel bacterium in gastritis and peptic ulcer diseases (43-44), as well as on the microplate analysis innovations. These innovations revolutionized microplate

analyses worldwide and have been utilized so extensively and successfully since the 70's, that they can justifiably be called global laboratory and industrial standards. They resulted, among other things, in rapid and massive development of reliable and safe non-radioactive microplate immunoassays, on which the GastroPanel biomarker ELISA-tests are based (45).

### GastroPanel innovation

The GastroPanel blood tests along with the GastroSoft report interpretation have been developed to determine the function and status of gastric mucosa (Figure and Table). The GastroPanel examination improves the diagnosis of dyspepsia, *H. pylori* infection and in most cases asymptomatic atrophic gastritis and their associated risks, and promotes correctly targeted, evidence-based and effective disease prevention and treatment in primary care. With the help of the GastroPanel examinations it is possible to diagnose reliably whether the gastric mucosa in a patient with dyspepsia-type complaints is "healthy" or "affected". The examination also determines whether the patient is at risk of complications associated with gastro-oesophageal reflux disease (GORD) due to high acid output (secretion). The GastroSoft report on GastroPanel results helps the doctor to refer the correct patients for a life saving gastroscopy and avoids gastroscopy procedures being performed on patients with a healthy gastric mucosa

(no *H. pylori* infection or atrophic gastritis) and normal stomach acidity. Up to 40 percent savings can be achieved with this procedure in endoscopy costs alone. Easily available and state of the art, safe and cost-effective, the GastroPanel blood tests encourage people with dyspepsia to consult a doctor in time, which promotes safe, ethical and cost-effective disease treatment and prevention based on a correct and early, potentially life-saving diagnosis.

Depending on the patient's age, 2 to 12 percent of the adult population has atrophic gastritis of the gastric mucosa (the loss of appropriate glands and function of the antrum and/or the corpus mucosa), either asymptomatic, or associated with dyspepsia-like symptoms and *H. pylori* infection. Previously, in most cases, asymptomatic atrophic gastritis could be detected only by means of invasive gastroscopy and histological examination of the collected biopsies. Now, this can be done in a simple and even more reliable way with the GastroPanel examination from a blood sample. Moreover, atrophic gastritis is associated with risks such as gastric or oesophageal cancer, peptic ulcer disease and vitamin B12, iron and calcium deficiencies, which increase the importance of the early diagnosis of atrophic gastritis caused by *H. pylori* infection or autoimmune diseases.

**GastroPanel examination** contains determinations of pepsinogen I, pepsinogen II and amidated gastrin-17 levels and *H. pylori* antibodies from a blood sample (plasma) and GastroSoft report (Figure 2). The GastroPanel tests are reimbursed by KELA – the Social Insurance Institution in Finland.

### **The acute need to develop a treatment practice for dyspepsia and *H. pylori* infection**

The various treatment practices of dyspepsia and *H. pylori* infection that are only based on *H. pylori* tests (the 13C urea breath test and stool antigen test)

and trial treatments with proton pump inhibitors (PPIs) do not enable doctors to provide the best possible, available, state-of-the-art, safe diagnosis, treatment and prevention of diseases, and thus are neither medically recommended nor cost-effective, as they can delay the correct diagnosis and treatment, or even result in serious malpractice (31, 35–37, Table).

The 13C urea breath test and stool antigen test or solely *H. pylori* antibody tests for dyspepsia and *H. pylori* infection are unable to detect atrophic gastritis caused by *H. pylori* infection or autoimmune diseases. In addition, the 13C urea breath test and stool antigen test may give even 50% false negative results if the patient has atrophic gastritis, MALT lymphoma or bleeding peptic ulcer disease, or if the patient is receiving antibiotics or PPI medication. Consequently, the 13C urea breath test and stool antigen test may give false negative results in the very cases where it is of particular importance to detect the *H. pylori* infection and where the patient should be treated, e.g. because of the risk of gastric cancer. *H. pylori* tests alone do not detect atrophic gastritis of the corpus and/or antrum mucosa (Table).

However, the reliable detection of *H. pylori* infection, atrophic gastritis and high acid output is particularly important as these conditions may progress into gastric and oesophageal cancer. For this reason, every dyspeptic and asymptomatic patient with atrophic gastritis, high acid output and untreated *H. pylori* infection with symptoms should be referred for a gastroscopy without delay and for any necessary treatment.

*H. pylori* infection and the precancerous lesions progressing from atrophic gastritis (intestinal metaplasia, dysplasia) due to *H. pylori* infection or an autoimmune disease have been observed to progress into gastric cancer. In cases where only an *H. pylori* infection diagnosis is made, even a successful *H. pylori* eradication treatment with antimicrobial medication and PPI medication cannot cure pre-

cancerous lesions or early stage cancer due to *H. pylori* infection and atrophic gastritis. Early diagnosis and surgical treatment is necessary to improve the prognosis and to prevent unnecessary deaths due to gastric cancers.

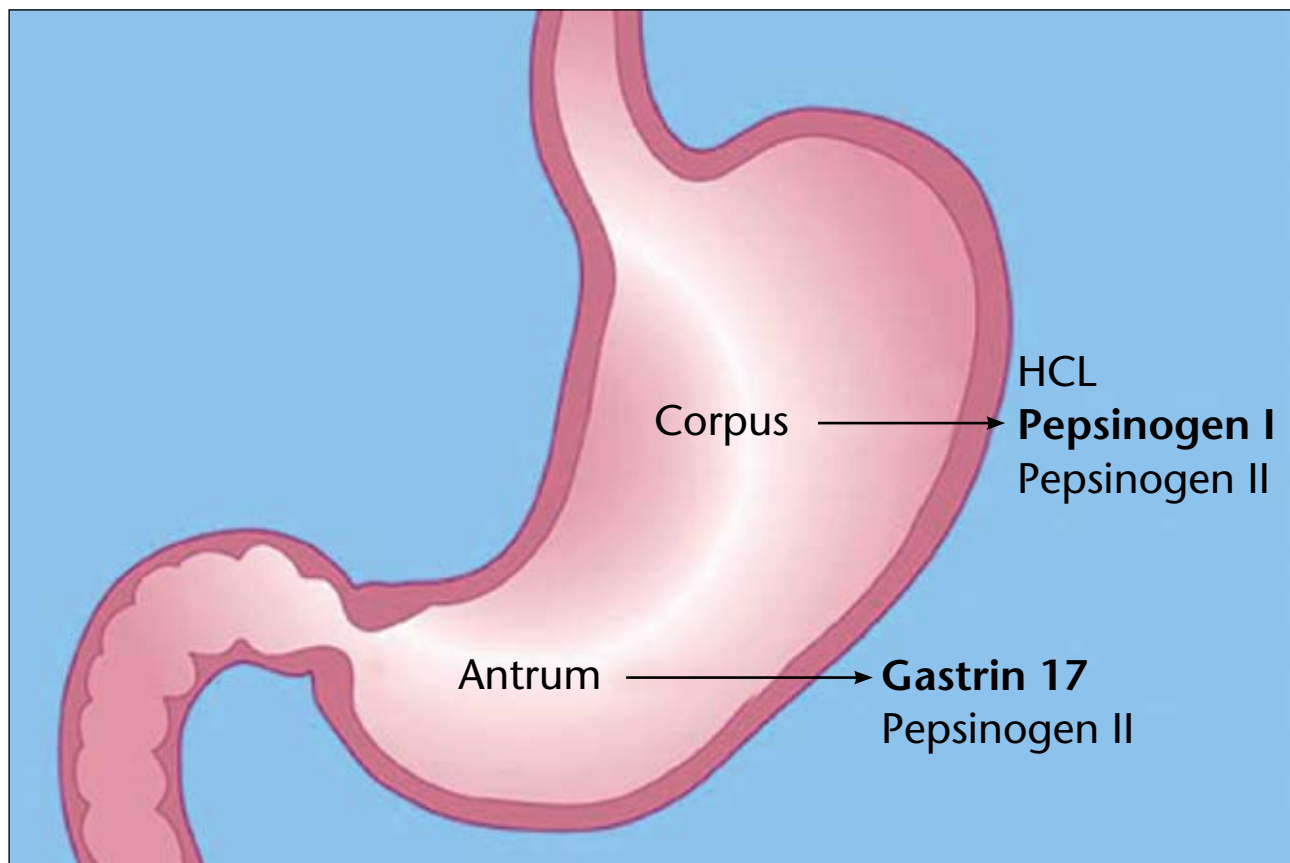
A normal GastroPanel result in a dyspepsia patient indicates that the gastric mucosa is healthy and functions normally, meaning that the patient does not have *H. pylori* infection (gastritis) or atrophic gastritis. Confirmation that the stomach does not show signs of gastritis is very important since it shows that the person with the dyspeptic complaints could have a non-gastric condition (e.g. biliary or pancreatic conditions, lactose intolerance, celiac disease) or a colorectal condition. High acid output increases a risk of the CORD complications, erosive oesophagitis and Barrett's oesophagus.

However, it must be recalled, that GastroPanel is not a gastric or oesophageal cancer test. It only reveals atrophic gastritis of the corpus mucosa that is caused by *H. pylori* infection or an autoimmune disease. GastroPanel also reveals atrophic gastritis of the antrum mucosa caused by *H. pylori* infection, which may strongly increase a risk of gastric cancer and peptic ulcer disease. Gastric cancer is thought to develop as a result of several consecutive changes as presented by Correa's cascade of gastric carcinogenesis (35). Moreover, GastroPanel reveals high acid output of the stomach (33).

Some gastric cancers, due to *H. pylori* infection, develop without histologically observable atrophic gastritis. Therefore, the early reliable diagnosis of *H. pylori* infection made by the GastroPanel examination might even be life saving (Table). A small proportion of gastric cancers are hereditary.

### **GastroPanel examination**

GastroPanel is recommended as a primary examination at any age, if the patient has dyspepsia including symptoms of GORD. GastroPanel is



**Figure.** The levels of the GastroPanel-biomarkers, pepsinogen I (PG I) and pepsinogen II (PG II), basal gastrin-17 (G-17b) and *H. pylori* antibodies measured from a plasma sample, diagnose atrophic gastritis of the entire mucosa of the stomach. *H. pylori* related gastritis usually starts in the antrum and expands proximally towards the corpus of the stomach. Stomach carcinogenesis is believed to begin with chronic active inflammation of the stomach mucosa, proceeding to extensive atrophy together with intestinal metaplasia, then to dysplasia and finally to cancer. When comparing GastroPanel and gastroscopy, accurate diagnosis of atrophic gastritis cannot always be made from a few biopsy specimens covering an area of 15-20 square millimetres of the adult gastric mucosal surface area (about 80 000 square millimetres). In addition, the diagnoses of two pathologists may diverge. The quality of gastroscopy is strongly dependent on the experience and competence of the gastroenterologist and pathologist. GastroPanel does not have such problems, irrespectively whoever conducts the GastroPanel blood tests. However, the diagnosis of atrophic gastritis obtained with GastroPanel is positively aligned with gastroscopy performed by skilful gastroenterologists and pathologists(4). Since atrophic gastritis together with intestinal metaplasia is a multifocal process, it is difficult to accurately diagnose the extent of atrophic gastritis based on the few biopsy samples. Furthermore, histological diagnosis of gastric atrophy depends on subjective judgment without a gold standard. Thus, there is a need for atrophic gastritis and its progression biomarkers, which are more convenient, free of discomfort or risk, economical and based on objective parameters (5). Endoscopic biopsy histology is not a reliable gold standard (1). Whilst histological diagnosis is the current “gold standard” for comparison with biomarkers, it has limitations in diagnostic accuracy (2, 3). When the GastroPanel biomarkers indicate the gastric mucosa is healthy (no *H. pylori* infection and/or no atrophic gastritis), the dyspepsia symptoms are often caused by functional dyspepsia or another disease not involving the gastric mucosa. GastroPanel can also be used to find the dyspepsia and gastroesophageal reflux patients who need gastroscopy as a further examination.

1. Iijima K, Abe Y, Kikuchi R, Koike T, Ohara S, Sipponen P, Shimosegawa T. Serum biomarker tests are useful in delineating between patients with gastric atrophy and a normal, healthy stomach. *World J Gastroenterol* 2009;15 (7):853-859.
2. Storskrubb T, Aro P, Ronkainen J, Sipponen P, Nyhlin H, Talley NJ, Engstrand L, Stolte M, Vieth M, Walker M and Agréus L. Serum biomarkers provide an accurate method for diagnosis of atrophic gastritis in a general population: The Kalixanda study. *Scand J Gastroenterol*, 2008; 43:1448-1455.
3. Ren JS, Kamangar F, Qiao YL, Taylor P, Liang H, Dawsey S, Liu B, Fan JH, Abnet C. Serum pepsinogens and risk of gastric and oesophageal cancers in the General Population Nutrition Intervention Trial cohort. *Gut*. 2009 Jan 9. [Epub ahead of print].
4. Väänänen H, Vauhkonen M, Helske T, Kääriäinen I, Rasmussen M, Tunturi-Hihnala H, Koskenpato J, Sotka M, Turunen M, Sandström R, Ristikankare M, Jussila A, Sipponen P. Non-Endoscopic Diagnosis of Atrophic Gastritis with a Blood Test. Correlation between Gastric Histology and Serum Levels of Gastrin-17 and Pepsinogen I. A Multicentre Study. *Eur J Gastroenterol Hepatol* 2003; 15: 885-891.
5. Yanaoka, K et al, Risk of gastric cancer in asymptomatic, middle-aged Japanese subjects based on serum pepsinogen and *Helicobacter pylori* levels, *Int. J. Cancer* 2008; 123: 917 – 926.

also the examination of choice, if the purpose is to screen for atrophic gastritis with associated risks in a "health check" of asymptomatic patients over 45 years of age. In addition to the reliable diagnosis of *H. pylori* infection and atrophic gastritis of the corpus and/or antrum mucosa, GastroPanel also provides information on high acid output (secretion) in the corpus of the stomach, which may increase the risks of complication in GORD patients. These include erosive oesophagitis and Barrett's oesophagus, both of which can progress into oesophageal cancer if left untreated.

High levels of gastrin-17 help to confirm the presence of atrophic gastritis of the corpus (diagnosed on the basis of pepsinogen I levels and/or the ratio of pepsinogen I and pepsinogen II) which can result in gastric and oesophageal cancer. Low levels of pepsinogen I and/or of pepsinogen I/pepsinogen II-ratio together with low levels of gastrin-17 indicate that the gastric mucosa is atrophied throughout. This is the most severe and significant risk factor for gastric cancer.

The levels of gastrin-17 in the blood reflect the structure and function of the lowermost part of the stomach (antrum). The GastroPanel gastrin-17 test measures the levels of gastrin-17 (amidated peptide hormone) with a specific receptor only in the parietal cells of the corpus of the stomach. Gastrin-17 is secreted exclusively by the G-cells of the antrum and it stimulates the gastric hydrochloric acid secretion of the parietal cells of the corpus. High hydrochloric acid secretion from the corpus, in turn, reduces gastrin-17 secretion from the antrum.

High fasting levels of gastrin-17 (over 10 pmol/l) in a GastroPanel examination usually indicate an achlorhydric stomach (from PPI medication or atrophic gastritis of the corpus mucosa). If an *H. pylori* infection is not detected after fasting, low levels of gastrin-17 only indicate high acid secretion of the corpus mucosa.

If the patient has an *H. pylori* infection, low fasting levels of gastrin-17

may indicate atrophic gastritis of the antral mucosa caused either by an infection or by high acid secretion of the corpus of the stomach, if the corpus is healthy (no atrophic gastritis). The cause of low levels of gastrin-17 can be determined by protein stimulation, which can be performed as early as the GastroPanel examination by also measuring fasting levels of gastrin-17 and protein-stimulated levels of gastrin-17 twenty minutes after protein solution intake. In atrophic gastritis of the antrum, low levels of gastrin-17 are not increased by protein stimulation (over 5 pmol/l), and the more severe the atrophic gastritis is, the less the low levels are increased by protein stimulation. If protein stimulation increases the low levels (over 5 pmol /l), the patient has no corpus atrophy and a very acidic stomach.

### Affected gastric mucosa

The GastroPanel examination provides a great deal of reliable information on whether the patient's gastric mucosa shows *H. pylori* infection and atrophic gastritis (10, 11). If the mucosa is affected, the examinations will also provide information on whether the patient just has non-atrophic *H. pylori* gastritis or an atrophic gastritis of the corpus (achlorhydric stomach), the antrum, or both. It will also provide information on the severity of the atrophic gastritis, evaluated in the GastroSoft report.

The <sup>13</sup>C urea breath and stool antigen tests for *H. pylori* infection diagnosis cannot detect atrophic gastritis as they only detect whether the patient has an ongoing *H. pylori* infection or not, nothing else (13–16). Therefore, neither test, nor the serological antibody tests, can be used to decide whether the gastric mucosa is atrophied or not, as can be done with the GastroPanel examination, or by means of a biopsy examination in connection with gastroscopy. GastroPanel is an examination that comprehensively reports on the health

of the stomach and the structure and function of the mucosa. Consequently, GastroPanel gives much more important information and is thus safer than simple *H. pylori* tests (Table, Figure).

The diagnostic reliability of GastroPanel is high (10, 11, 17, 18). In a study conducted in northern Sweden on a population of 1,000 people, the sensitivity and accuracy of GastroPanel was 89% (86%–91%) and 90% (86%–93%) compared with gastroscopy-biopsy examination. GastroPanel focused on detecting whether the gastric mucosa was healthy or not (11). In a similar study in Japan, the sensitivity and accuracy were 95% and 93% respectively (17). GastroPanel reliably detects atrophic gastritis (10, 24). In such patients, further evaluation (e.g. by gastroscopy and histological biopsy examination) is necessary due to the risks associated with the condition and these patients should be referred for consultation with a specialist irrespective of the patient's age (12).

### Healthy gastric mucosa — very low risk of gastric conditions regardless of patient age

From the clinical praxis perspective, a dyspepsia patient with a "healthy" gastric mucosa (meaning that there is no *H. pylori* infection and no atrophic gastritis) means a very low risk or likelihood of gastric disease conditions. Therefore, abdominal complaints in such patients are likely not to be caused by a gastric condition, but by something else.

Since the likelihood of gastric conditions is practically non-existent in such dyspepsia patients, gastroscopy as a routine examination is often a waste of resources. This also applies to elderly patients with dyspeptic complaints, which often are due to colorectal conditions (12).

According to various guidelines issued several years ago, gastroscopy should always be performed in dyspepsia patients over the age of 45–55

**Table.** Summary of the data provided by the GastroPanel examination and the <sup>13</sup>C- urea breath test or stool antigen test of the “test and treat” strategy. The reports produced by GastroSoft are based on clinical studies comparing the results of GastroPanel examinations with results from gastroscopy and biopsy specimen examinations. The serious medical and ethical problems of the “test and treat” strategy can be corrected simply and economically by replacing its <sup>13</sup>C- urea breath test or stool antigen test with the GastroPanel examination.

| GastroPanel   | The GastroSoft report states: | <sup>13</sup> C - urea breath test or Stool antigen test report: |
|---|-------------------------------|--|
| <b>The diagnosis for</b>  |                               |  |
| <b>Functional vs. organic dyspepsia.</b>  | YES                           | NO   |
| When GastroPanel indicates the gastric mucosa is healthy, the dyspepsia complaints are often caused by functional dyspepsia or another disease not involving the gastric mucosa |                               |  |
| <b>H. pylori infection</b> (gastritis)  | YES                           | NOT RELIABLE (1)   |
| <b>Atrophic gastritis</b> (damaged and severely dysfunctional gastric mucosa of the corpus or antrum or both)   | YES                           | NO   |
| <b>The risks (due to atrophic gastritis) of</b>   |                               |  |
| <b>Gastric cancer (in antrum and / or corpus)</b>   | YES (2)                       | NO   |
| <b>Vitamin B12 deficiency (corpus)</b>  | YES                           | NO   |
| <b>Calcium, zinc and iron deficiency (corpus)</b>   | YES (7)                       | NO   |
| <b>Peptic ulcer disease (antrum)</b>  | YES (3)                       | NO   |
| <b>The risks of GORD complications</b>  |                               |  |
| <b>Oesophagitis and Barrett’s oesophagus</b>  | YES (4)                       | NO   |
| <b>If necessary, a recommendation for</b>   |                               |  |
| Gastroscopy and biopsy examination  | YES                           | NO   |
| Treatment of <i>H. pylori</i> infection   | YES (8)                       | NOT RELIABLE (1)   |
| Determination of vitamin B12 and homocysteine   | YES                           | NO   |
| Determination of calcium and iron   | YES                           | NO   |
| Follow-up examination to monitor  |                               |  |
| the incidence of atrophic gastritis   | YES (5)                       | NO   |
| the healing of the <i>H. pylori</i> infection   | YES                           | NOT RELIABLE (1)   |
| the possible healing of atrophic gastritis  | YES                           | NO   |

- The <sup>13</sup>C- urea breath test and stool antigen test may give up to 50 % false negative results if the patient has a) atrophic gastritis and related risks, b) MALT lymphoma or c) bleeding peptic ulcer disease or d) if the patient is currently receiving antibiotics or PPIs (proton pump inhibitors). The GastroPanel *H. pylori* antibody test does not have these types of false negative results.
- The risk of gastric cancer is very low without atrophic gastritis in the corpus, antrum or both. But in some cases, a *H. pylori* infection without histologically observable atrophic gastritis may be associated with gastric cancer and peptic ulcer disease.
- No peptic ulcer disease with corpus atrophy (no acid, no ulcer). The risk of peptic ulcer disease is very low without antrum atrophy.
- Normal or high pepsinogen I and / or pepsinogen I and pepsinogen II ratio in association with low gastrin-17 (below 1,0 pmol /l) may indicate high acid (HCl) output and risks for the complications of gastro-oesophageal reflux disease (GORD).
- When the incidence of *H. pylori* -related atrophic gastritis is monitored, the patient can be offered targeted, safe treatment at the right time. The need for medication and the costs and adverse effects of medication can thus be reduced. If the patient has been diagnosed with peptic ulcer disease (gastric or duodenal ulcer), *H. pylori* infection has to be treated (6). If the patient has atrophic gastritis this should also be treated. The patient and the doctor may also agree on eradication treatment for other reasons for example when the patient’s close relatives have been diagnosed with gastric cancer.
- Press Release: The 2005 Nobel Prize in Physiology or Medicine, 3 October 2005 jointly to Barry Marshall and J. Robin Warren for their discovery of “the bacterium *Helicobacter pylori* and its role in gastritis and peptic ulcer disease”: “An indiscriminate use of antibiotics to eradicate *Helicobacter pylori* also from healthy carriers would lead to severe problems with bacterial resistance against these important drugs. Therefore, treatment against *Helicobacter pylori* should be used restrictively in patients without documented gastric or duodenal ulcer disease.” <http://nobelprize.org/medicine/laureates/2005/press.html>
- Adequate absorption of dietary calcium requires normal acid secretion that is impaired in atrophic gastritis and in long term PPI therapy. Subsequently, calcium is not absorbed normally in the gut and the subjects are at risk of osteoporosis and hip fracture. Hypochlorhydric states such as atrophic gastritis and partial gastrectomy have long been known to cause iron deficiency anaemia.
- Pepsinogen II level below 10 µg /l two months after the treatment indicates that the *H. pylori* eradication is succeeded. Increased level of pepsinogen II (over 10 µg /l) indicates active *H. pylori* gastritis or inflammation due to the use of non-steroidal anti-inflammatory drugs (e.g. aspirin) or strong alcohol. Dig. Liver Dis. 2005 Jul; 37(7):501-8. Epub 2005 Apr 18.

(19). These guidelines are outdated and often not followed, due to lack of resources, and this is why doctors often settle for trial medication. This may lead to a situation in which the patient chooses another doctor or risky self care. Nowadays delayed correct diagnosis is more common and self medication occurs more readily than before in Finland, as PPI medication are now available from pharmacies without prescription. PPIs and yoghurts are aggressively and heavily advertised for stomach complains.

The most feared causes of dyspepsia are oesophageal or gastric cancers. According to statistics, the average prevalence and incidence of gastric cancer increases steeply with age. However, cancer incidence is primarily associated with *H. pylori* gastritis and atrophic gastritis caused by an *H. pylori* infection or an autoimmune disease, the prevalence of which in the population increases with age. However, age is not an independent risk factor for gastric cancer (6). The likelihood of gastric cancer and other significant gastric conditions is equally low in 70-year-old Finns with a "healthy" stomach (gastric mucosa) and in 30-year-olds with a "healthy" stomach (20).

The most important uses for the GastroPanel examination are in primary care. The examinations give the physician an opportunity to improve an early, safe and cost-effective treatment chain that is based on objective evidence. Physicians in primary care have not had such an opportunity before the introduction of the GastroPanel examination. If GastroPanel reveals atrophic gastritis, high acid output or untreated *H. pylori* infection with symptoms, the dyspeptic and asymptomatic patients should be referred for a potentially life-saving gastroscopy without delay and for any necessary treatment.

### Cost savings in endoscopy

With respect to the specificity of dyspepsia diagnoses, performing gastroscopies with their associated histologi-

cal biopsy examinations in all patients would naturally be the best option, which is also the orthodox medical approach. However, lack of resources and the incurrent costs have limited this strategy. Now, however, medical support and cost savings can be combined as follows.

Computational savings can be achieved when invasive, expensive and sometimes even risky gastroscopic examinations are reduced with easy and safe GastroPanel examination and the resources saved can then be used for other procedures, e.g. other endoscopies (21).

The prevalence of healthy gastric mucosa in Finnish patients with dyspepsia has varied between 50 percent and 70 percent in recent surveys (1, 10, 11, 22). If the estimated prevalence of persons with a healthy stomach is 60 percent, the estimated costs of gastroscopy and biopsy examination are €400, and the costs of GastroPanel examination are €90. In endoscopic examinations, it is possible to achieve 40 percent cost savings. These cost savings will be obtained if a GastroPanel examination is performed first on all patients, and no gastroscopic examination performed when the GastroPanel results are normal (i.e. a gastric mucosa without *H. pylori* infection and atrophic gastritis).

With this procedure, the cost savings could be approximately €150,000 per year per 1,000 dyspepsia patients. Taking into account the whole population, these savings would be very sizeable (the prevalence of dyspepsia in Finland is one third of the population of 5.3 million). This procedure would not put patients' health at risk. The chances that some significant gastric condition due to *H. pylori* infection and atrophic gastritis (such as peptic gastric ulcer, duodenal ulcer or gastric cancer) would be left undetected and untreated would be minimal.

The cost savings described above naturally depend on the unit costs of the examinations and especially on how well the guideline of "no gastroscopy

on persons with a healthy stomach" is followed. Cost savings increase with a general rise in "healthy" stomachs within the population. Cost savings are approximately 50% if the proportion of persons with a healthy stomach is 70 percent.

### Savings concerning early diagnosis and prevention

Safe, ethical and cost-effective diagnosis, treatment and prevention of conditions associated with dyspepsia-type complaints can be developed and reduce the costs for healthcare, improve quality of life and help people manage longer in working life.

1. Dyspepsia patients with *H. pylori* infection and atrophic gastritis caused by an *H. pylori* infection or an autoimmune disease should always be diagnosed or excluded using a GastroPanel examination and considered before prescribing PPI medication for dyspepsia and GORD or providing antimicrobial and PPI eradication therapy for an *H. pylori* infection.

The simple and unreliable *H. pylori* tests offered for the diagnosis of dyspepsia and *H. pylori* infection cannot detect, in most cases, asymptomatic atrophic gastritis, which is also why the risks associated with this condition will remain unexplored. Moreover, the <sup>13</sup>C urea breath tests and stool antigen tests may give up to 50% false negative results for *H. pylori* infection if the patient has atrophic gastritis, MALT lymphoma or a bleeding peptic ulcer disease or if the patient is currently receiving antibiotics or PPI medication. In addition, the *H. pylori* tests do not reveal high acid output. The GastroPanel examination does not have these serious medical and ethical problems (Table and Appendix 1).

2. PPI medication or PPI medication and antimicrobial *H. pylori* eradication therapy do not cure early gastric cancer caused by *H. pylori* infection nor conditions associated with atro-



**Appendix. - The GastroPanel and Acetium innovations are together a unique combination that can help to prevent gastric and oesophageal cancers.** GastroPanel detects atrophic gastritis and the related gastric and oesophageal cancer risks while the conditions are still treatable. Atrophic gastritis of the corpus, which is usually irreversible, leads to permanent achlorhydria. In an achlorhydric stomach, microbes from the mouth can survive and produce acetaldehyde from sugars and alcohol present in food (1). In the new cancer classification issued by WHO in October 2009, acetaldehyde present in alcoholic beverages and formed from ethanol endogenously is in Group 1, together with carcinogens such as asbestos, tobacco and benzene (2).

Globally, acetaldehyde exposure mediated by gastrointestinal tract microbes or tobacco smoke is associated with approximately four million new cases of cancer each year, nearly 40 per cent of all cancers. These include upper aerodigestive tract, colon and pulmonary cancers (3). Biohit has developed products and a method to reduce physical and nutritional exposure to acetaldehyde (4-7).

**The same ethical and legislative principle concerns all Group I carcinogens, regardless of the source of the carcinogen.** Physical and nutritional exposure to them should be reduced by all means possible. The Acetium capsule, protected by patents, is the only means of inactivating carcinogenic acetaldehyde in the stomach, thus helping to prevent gastric and oesophageal cancers. Acetium capsules are available over the counter without prescription. They are recommended at meals and when consuming alcohol for those with

1. achlorhydria caused by atrophic gastritis (diagnosed by GastroPanel)
2. an untreated *Helicobacter pylori* infection (diagnosed by GastroPanel)
3. a long term use of antacids (PPIs, H2-receptor antagonists)
4. a resected stomach.

It will take years to obtain conclusive information on Acetium's efficiency in the prevention of gastric and oesophageal cancer. We will need population studies targeted at high-risk groups and aiming for systematic reduction of acetaldehyde exposure. Unfortunately, randomised intervention studies on Acetium are not possible for ethical reasons, due to the Group 1 carcinogenicity classification of acetaldehyde ([www.acetium.com/test](http://www.acetium.com/test) reveals acetaldehyde exposure).

#### Literature

1. Väkeväinen et al. Scand. J. Gastroenterol 2002;37:648-655
2. Secretan B, Straif K, Baan R, Grosse Y, ElGhissasi F, Bouvard V et al. A review of human carcinogens-Part E: tobacco, areca nut, alcohol, coal smoke, and salted fish. [www.the-lancet.com/oncology](http://www.the-lancet.com/oncology). Vol10, November 2009.
3. Salaspuro M. Acetaldehyde as a common denominator and cumulative carcinogen in digestive tract cancers. Scand J Gastroenterol 2009; 44:912-25.
4. Salaspuro V, Hietala J, Kaihovaara P, Pihlajarinne H, Marvola M, Salaspuro M. Removal of acetaldehyde from saliva by a slow-release buccal tablet of L-cysteine. Int J Cancer 2002;97:361-4.
5. Salaspuro VJ, Hietala JM, Marvola ML, Salaspuro MP. Eliminating carcinogenic acetaldehyde by cysteine from saliva during smoking. Cancer Epid Biomark Prev 2006;15:146-9.
6. Kartal A, Hietala J, Laakso I, Kaihovaara P, Salaspuro V, Sakkinen M, et al. Formulation and in vivo evaluation of L-cysteine chewing gums for binding carcinogenic acetaldehyde in the saliva during smoking. J Pharm Pharmacol. 2007;59:1353-8.
7. Linderborg K, Marvola T, Marvola M, Salaspuro M, Färkkilä M, Väkeväinen S. Reducing carcinogenic acetaldehyde exposure in the achlorhydric stomach with cysteine. Alcoholicm Clin Exp Res, 2011;35:1-7.

phic gastritis, such as precancerous lesions or early gastric cancer (27). PPI medication, which induces an achlorhydric stomach and is very often used without an exact diagnosis to alleviate dyspepsia-type complaints (e.g. stomach pain and heartburn), and often eliminates these complaints thereby delaying the correct diagnosis and treatment, with potentially fatal consequences.

3. The Pharmaca Fennica entry (2009, III, p. 1829) for a PPI product includes the following warning: *“If the patient has alarming symptoms (e.g. significant, unexplained weight loss, repeated vomiting, dysphagia, haematemesis or melaena) and a suspected or diagnosed gastric ulcer, the possibility of malignancy should first be excluded since PPI therapy may alleviate the symptoms and delay the diagnosis.”* - Unfortunately, this warning is very often too late.

4. The National Cancer Institute (Bethesda, MD) published an article together with the Cancer Institute & Hospital, Chinese Academy of Medical Sciences (Beijing) in 2008 confirming earlier results that year that atrophic gastritis of the corpus (achlorhydric stomach and associated carcinogenic acetaldehyde produced by microbes of the mouth) may increase the risk of oesophageal cancer (24). The study showed that the GastroPanel tests, pepsinogen I and II, can detect atrophic gastritis of the corpus even more reliably than biopsy examinations performed in connection with gastroscopy.

5. In the treatment of osteoporosis, the following should be taken into account to improve cost-effectiveness: a possible achlorhydric stomach, the result of PPI medication and atrophic gastritis of the corpus, which is, in most cases, asymptomatic and which can be detected with a GastroPanel examination. Calcium deficiency due to an achlorhydric stomach is a cause of osteoporosis and therefore increases the risk of hip fractures (26). There are

35,000 to 40,000 osteoporosis-related fractures per year in Finland. Besides the human tragedy, hip fractures alone (approximately 7,000/year) cause moderately estimated healthcare costs of over €100 million a year (The Finnish Medical Journal 22/2008, vol. 63, pp. 2033–40). This number may increase as the population ages.

6. When the goal is to obtain cost savings in healthcare, it should be taken into account that patients with autoimmune conditions, such as ulcerative colitis, thyroiditis, diabetes, MS, SLE and rheumatoid arthritis, may have concurrent asymptomatic atrophic gastritis of the corpus with its associated risks, such as gastric and oesophageal cancer and vitamin B12 deficiency, caused by an autoimmune disease. Vitamin B12 deficiency is increasing as the population ages and is developing into a public health problem (34). Vitamin B12 deficiency may cause dementia, depression, polyneuropathy and a high concentration of homocysteine in the body. This is thought to be an independent risk factor for atherosclerosis, heart attacks and strokes. The GastroPanel examination could undoubtedly promote safe treatment and reduce the days spent in institutional and hospital care, as well as reduce other treatment and sickness-leave costs and alleviate human suffering. Tests to examine the causes of these conditions could take place in outpatient or hospital care or in institutions for the elderly or the mentally disabled.

7. Based on the Finnish Setti studies, conducted over ten years ago and on the follow-up of the study subjects, it has been estimated that GastroPanel screening of people of 45 years through early detection of *H. pylori* infection and asymptomatic atrophic gastritis and referral for gastroscopy and biopsy examination would improve the prognosis of 250 to 300 patients with precancerous lesions or early gastric cancer (8, 9).

A Finnish Medical Journal article suggests that GastroPanel would be particularly suitable for assessing the risks of asymptomatic patients when the primary aim is the early diagnosis of gastric and oesophageal cancer, e.g. the screening (preselecting) of patients with atrophic gastritis who should be referred for a gastroscopy (32). However, it should be kept in mind that a small proportion of gastric cancers are hereditary and some *H. pylori* infections may progress into gastric cancer even if no microscopic atrophic gastritis is detected in the histological biopsy examination.

8. The GastroPanel examination also provides information on the risk of peptic ulcer disease caused by an *H. pylori* infection. Peptic ulcer diseases and the use of anti-inflammatory analgesics cause complications (e.g. bleeding) that cause 200 to 300 deaths each year in Finland (30).

9. Based on the above, the risk of oesophageal cancer would seem to be increased by: 1) the acidic stomach content that flows back into the oesophagus, which is why the stomach is “treated” to become achlorhydric with PPI medication (there were close to 10% of the population (464,000) on PPI medication in Finland who received sickness insurance reimbursements by the Social Insurance Institution in 2007, *Lääkeinfo*, The Finnish Medical Journal 4/2009, vol. 64, p. 296–299); or 2) carcinogenic acetaldehyde produced by microbes in an achlorhydric stomach caused by atrophic gastritis of the corpus. About 500 million people worldwide have an achlorhydric stomach due to corpus atrophy.

In an achlorhydric stomach caused by atrophic gastritis of the corpus due to *H. pylori* infection, autoimmune disease or PPI medication, oral microbes can multiply and produce carcinogenic acetaldehyde from the sugars and alcohol that are a part of a normal diet. Acetium capsules taken with meals are available to inactivate

acetaldehyde produced in the stomach. At the moment, Acetium capsules are currently available in Finnish pharmacies ([www.acetium.com/test](http://www.acetium.com/test) reveals acetaldehyde exposure, see Appendix).

10. The GastroPanel examination warns of the complication risks of GORD associated with an acidic stomach. Erosive oesophagitis and Barrett's oesophagus are asymptomatic in as many as one third of reflux patients and which can progress into oesophageal cancer if left untreated. Some researchers recommend GastroPanel for differential diagnosis of non-erosive reflux disease (NERD) and erosive reflux disease (ERD) and an effective PPI medication for ERD only (Gut 2006; 55 suppl VA 267). In the gastroenterology symposium held in Helsinki in 2008, neither Finnish nor foreign researchers could give a clear answer as to when and how often a patient with GORD should be referred for a gastroscopy in the absence of alarming symptoms clearly demanding immediate gastroscopy.

It is clear that endoscopies are performed too rarely and possibly also too late, since the  $^{13}\text{C}$  urea breath tests and stool antigen tests for instance fail to provide information on the potential complication risks of GORD in dyspepsia patients, asymptomatic patients wanting a health check, or patients with atrophic gastritis. If the GastroPanel examination shows that the content of the stomach is highly acidic, even an asymptomatic GORD patient may have a complication risk of GORD. In these cases especially an endoscopy and the required treatment are recommended.

## Conclusion

Depending on the patient's age, 2 to 12 percent of the adult population has atrophic gastritis of the gastric mucosa caused by *H. pylori* infection or an autoimmune disease that in most cases is asymptomatic or associated with dyspepsia-like symptoms.

Before the GastroPanel innovation, atrophic gastritis could be detected only with an invasive gastroscopy and histological examination of the biopsies collected in connection with the procedure. The diagnosis of atrophic gastritis, its location (corpus or antrum or both) and its severity can now be detected in a simpler, more reliable way with GastroPanel examination, which outperforms plain *H. pylori* tests and is performed on a blood sample and includes the GastroSoft report (10, 11, 17, 23–25).

When people with dyspepsia who have not had appropriate examinations and treatment find out about how the GastroPanel examination can be performed safely and easily on a blood sample (many are afraid of invasive gastroscopy), many with dyspepsia-type complaints may not stay home anymore and wait for their condition to worsen, and many others might give up risky self medication (with over-the-counter products, using PPIs and certain yoghurts for abdominal discomfort and heartburn) and seek examination and treatment in time.

If a patient with dyspepsia or wanting a health check does not have any alarming symptoms requiring immediate gastroscopy, it is recommended that the state of the art GastroPanel is used as a primary examination to secure the early selection of right patients for refer-

ral for endoscopy and to promote the development of safe, ethical and cost-effective diagnosis and prevention of diseases (Table, Figure and Appendix). If the GastroPanel examination reveals atrophic gastritis, high acid output or an untreated *H. pylori* infection with symptoms, the dyspeptic and asymptomatic patients should be referred for a potentially lifesaving gastroscopy without delay and for any necessary treatment.

Osmo Suovaniemi, M.D, Ph.D, Professor  
Chairman, Biohit Oyj, [www.biohit.com](http://www.biohit.com)  
[osmo.suovaniemi@biohit.com](mailto:osmo.suovaniemi@biohit.com)  
Tel +358 – 9 – 773 861

The Chairman and Founder of Biohit Oyj, Professor Osmo Suovaniemi, M.D., Ph.D., was also the Founder of Labsystems Oyj (est. 1971, the first OTC company listed on the stock exchange in Finland in 1984) and the joint venture Eflab Oy (est. 1978 by the family Suovaniemi and the American company Flow General Inc.). These companies have "revolutionised laboratory routines worldwide in the 1970s and 1980s" through Suovaniemi's innovations in the *adjustable single- and multi-channel Finnpiettes and vertical measurement principle* (Suovaniemi equation,  $A = km$ , where A is absorbance, k is a constant and m is a mass to be measured) for non-radioactive and safe microplate immunoassays, analysers and analysing systems (TEKES, The National Technology Agency of Finland 2001: These innovations are "Paving the Way for Evidence Based Medicine"). Since its establishment Biohit has also applied Suovaniemi's *aggressive innovation and patenting strategy*. In January 2000, twenty new companies listed on the Helsinki stock exchange altogether possessed 11 patents, whereas Biohit alone possessed 16 patents in Finland ([www.biohit.com/About Us/History: Aggressive Innovation and Patenting Strategy](http://www.biohit.com/About Us/History: Aggressive Innovation and Patenting Strategy) and [www.google.com / search Suovaniemi equation](http://www.google.com/search?q=suovaniemi+equation)). Diagnostic products, such as the GastroPanel examination, are components for company's analysing systems and more generally for the *vertical measurement principle* based microplate analysers and analysing systems world-wide (hundreds of thousands on the market place).

## Literature

1. Rehnberg-Laiho L, Salomaa A, Rautelin H, Koskela P, Sarma S, Kosunen TU. Accelerated decline in *Helicobacter pylori* seroprevalence rate during the screen and treat project in Vammala, Finland, as demonstrated in 29 to 45-year-old pregnant women. *APMIS* 2004;112:348.
2. Sipponen P, Helske T, Järvinen P, Hyvärinen H, Seppälä K, Siurala M. Fall in the prevalence of chronic gastritis over 15 years: analysis of outpatient series in Finland from 1977, 1985, and 1992. *Gut* 1994;35:1167-71.
3. Carmack SW, Genta RM. *Helicobacter pylori* seroprevalence in symptomatic veterans: a study of 7310 patients over 11 years. *Helicobacter* 2009;14:298-302.
4. Valle J, Kekki M, Sipponen P, Ihamäki T, Siurala M. Long-term course and consequences of *Helicobacter pylori* gastritis. Results of a 32 year follow-up study. *Scand J Gastroenterol* 1996;31:546-50.
5. Correa P, Haenszel W, Cuello C, Zavala D, Fonstam E, Zarama G, Tannenbaum S, Collazos T, Ruiz B. Gastric precancerous process in a high risk population: cohort follow-up. *Cancer Res* 1990;50:4737-40.
6. Sipponen P, Kekki M, Haapakoski J, Ihamäki T, Siurala M. Gastric cancer risk in chronic atrophic gastritis: statistical calculations of cross-sectional data. *Int J Cancer* 1985;35:1737.
7. Knekt P, Teppo L, Aromaa A, Rissanen H, Kosunen TU. *Helicobacter pylori* IgA and IgG antibodies, serum pepsinogen I and the risk of gastric cancer: changes in the risk with extended follow-up period. *Int J Cancer* 2006;119:702-5.
8. Sipponen P, Varis K, Fräki O, Korri UM, Seppälä K, Siurala M. Cumulative 10-year risk of symptomatic duodenal and gastric ulcer in patients with or without chronic gastritis. A clinical follow-up study of 454 outpatients. *Scand J Gastroenterol* 1990;25:966-73.
9. Sipponen P, Seppälä K, Äärynen M, Helske T, Kettunen P. Chronic gastritis and gastroduodenal ulcer: a case control study on risk of coexisting duodenal or gastric ulcer in patients with gastritis. *Gut* 1989;30:922-9.
10. Väänänen H, Vauhkonen M, Helske T, Kääriäinen I, Rasmussen M, Tunturi-Hihnalä H, Koskenpato J, Sotka M, Turunen M, Sandström R, Ristikankare M, Jussila A, Sipponen P. Non-endoscopic diagnosis of atrophic gastritis with a blood test. Correlation between gastric histology and serum levels of gastrin-17 and pepsinogen I: a multicentre study. *Eur J Gastroenterol Hepatol* 2003;15:885-91.
11. Storskrubb T, Aro P, Ronkainen J, Sipponen P, Nyhlin H, Talley NJ, Engstrand L, Stolte M, Vieth M, Walker M and Agréus L. Serum biomarkers provide an accurate method for diagnosis of atrophic gastritis in a general population: The Kalixanda study. *Scand J Gastroenterol*, 2008; 43:1448-55.
12. Sipponen P, Graham DY. Importance of atrophic gastritis in diagnostics and prevention of gastric cancer: application of plasma biomarkers. *Scand J Gastroenterol* 2007; 42: 2-10.
13. Karnes WE Jr, Samloff IM, Siurala M, Kekki M, Sipponen P, Kim SW, Walsh JH. Positive serum antibody and negative tissue staining for *Helicobacter pylori* in subjects with atrophic body gastritis. *Gastroenterology*. 1991;10: 167-74.
14. Kokkola A, Rautelin H, Puolakkainen P, Sipponen P, Färkkilä M, Haapiainen R, Kosunen TU. Diagnosis of *Helicobacter pylori* infection in patients with atrophic gastritis: comparison of histology, 13C urea breath test, and serology. *Scand J Gastroenterol*. 2000; 35: 138-41.
15. Gatta L, Vakil N, Ricci C, Osborn JF, Tampieri A, Perna F, Miglioli M, Vaira D. Effect of proton pump inhibitors and antacid therapy on 13C urea breath test and stool test for *Helicobacter pylori* infection. *Am J Gastroenterol* 2004; 99: 823-29.
16. Graham DY, Opekun AR, Hammoud F, Yamaoka Y, Reddy R, Osato MS, El-Zimaity HM. Studies regarding the mechanism of false negative urea breath tests with proton pump inhibitors. *Am J Gastroenterol* 2003; 98: 1005-9.
17. Iijima K, Abe Y, Kikuchi R, Koike T, Ohara S, Sipponen P, Shimosegawa T. Serum biomarker tests are useful in delineating between patients with gastric atrophy and a normal, healthy stomach. *World J Gastroenterol* 2009;15:853-9.
18. Dinis-Ribeiro M, Yamaki G, Miki K, Costa-Pereira A, Matsukawa M, Kurihara M. Meta-analysis on the validity of pepsinogen test for gastric carcinoma, dysplasia or chronic atrophic gastritis screening. *J Med Screen* 2004;11:141-7.
19. Malfertheiner P, Mégraud F, O'Morain C, Bazzoli F, ElOmar E, Graham D, Hunt R, Rokkas T, Vakil N, Kuipers EJ. Current concepts in the management of *Helicobacter pylori* infection: the Maastricht III Consensus Report. *Gut* 2007;56:772-81.
20. Pentti Sipponen, Matti Härkönen, Mikko Salaspuro. Atofifinen gastritti jää usein liian vähälle huomiolle. *Suomen Lääkärilehti* 2008;63:1428-30.
21. Koskinen SM, Putkonen P, Ruuska P, Jauhonen PV. Cost evaluation of GastroPanel in dyspepsia patients over 50 years of age. *Gut* 2005;54 (Suppl VI):A91
22. Kosunen TU, Aromaa A, Knekt P, Salomaa A, Rautelin H, Lohi P, Heinonen OP. *Helicobacter* antibodies in 1973 and 1994 in the adult population of Vammala, Finland. *Epidemiol Infect* 1997;119:29-34.
23. Yanaoka, K et al, Risk of gastric cancer in asymptomatic, middle-aged Japanese subjects based on serum pepsinogen and *Helicobacter pylori* levels. *Int. J. Cancer* 2008; 123: 917-926.
24. Ren JS, Kamangar F, Qiao YL, Taylor P, Liang H, Dawsey S, Liu B, Fan JH, Abnet C. Serum pepsinogens and risk of gastric and oesophageal cancers in the General Population Nutrition Intervention Trial cohort. *Gut*. 2009 Jan 9. [Epub ahead of print]
25. Pasechnikov VD, Chukov SZ, Kotelevets SM, ym. Invasive and non-invasive diagnosis of *Helicobacter pylori*-associated atrophic gastritis: A comparative study, *Scand J Gastroenterol* 2005; 40:297-301.
26. Yang YX, Lewis JD, Epstein S, et al. Long-term proton pump inhibitor therapy and risk of hip fracture. *JAMA* 2006; 296:2947-53.
27. Arkkila P, Kokkola A, Ristimäki A, Sipponen P. Gastric cancer in patients after eradication of *H. pylori* infection, A study of Helsinki University Central Hospital, Helsinki, Finland, "DDW abstract 2007"
28. Färkkilä M, Miten dyspepsia tulisi hoitaa, *Duodecim* 2004; 120: 2537- 42.
29. Färkkilä M, Kaksiportainen menetelmä seulo dyspepsia sairastavat, *Wyeth News to Doctors* 2005.
30. Karvonen A-L, Vatsavaivaa – Milloin tutkimuksiin, Mehiläinen, Terveydenhuolto Yksityisesti, 3 – 2006, sivut 89.
31. Suovaniemi O. GastroPanel dyspepsian, helikobakteeri-infektion ja atrofisen gastritin ja siihen liittyvien riskien turvallisen tutkimus- ja hoitokäytännön kehittämiseen, *Erilispainos Yksityislääkäri* 2006; 5. (In English) [www.biohit.com / Diagnostics / Literature](http://www.biohit.com / Diagnostics / Literature).
32. Karvonen AL, Ylävatsavaivan diagnostiikka: pitääkö aina tähyystää? *Suomen Lääkärilehti* 44/2005;60:4487-4490.
33. Sipponen P, Vauhkonen M, Helske T, et al. Patients with Barrett's oesophagus show low circulating levels of gastrin-17, *World J Gastroenterol* 2005; 11(38): 5988-5992.
34. Sipponen P, Laxen F, Huotari K, et al. Prevalence of Low Vitamin B12 and High Homocysteine in Serum in an Elderly Male Population: Association with Atrophic Gastritis and *Helicobacter pylori* infection, *Scand J Gastroenterol* 2003; 38:1209-1216.
35. Correa P. Human gastric carcinogenesis: a multistep and multifactorial process. First American Cancer Society Award Lecture on Cancer Epidemiology and Prevention. *Cancer Res* 1992;52:6735-6740[Abstract].
36. Borch K, Axelsson K, Halgreen H, Damkjaer Nielsen M, Ledin T, Szesci PB. The ratio of Pepsinogen A to Pepsinogen C: A sensitive Test for Atrophic Gastritis. *Scand J Gastroenterol* 1989; 24: 870-876
37. Dinis-Ribeiro M, da Costa-Pereira A, Lopes C, Barbosa J, Guilherme M, Moreira-Dias L, Lomba-Viana H, Silva R, Abreu N, Lomba-Viana R. Validity of Serum Pepsinogen I/II Ratio for the Diagnosis of Gastric Epithelial Dysplasia and Intestinal Metaplasia during the Follow-Up of Patients at Risk for Intestinal-Type Gastric Adenocarcinoma. *Neoplasia* 2004; 6(5):449-456.
38. Germana B, Di Mario F, Cavallaro LG, Moussa AM, Lecis P, Liatoupolou S, Comparato G, Carloni C, Bertiato G, Battistelli M, Papa N, Aragona G, Cavestro GM, Iori V, Merli R, Bertolini S, Caruana P, Franze A. Clinical usefulness of serum pepsinogens I and II, gastrin-17 and anti-*Helicobacter pylori* antibodies in the management of dyspeptic patients in primary care. *Digestive and Liver Disease* 2005;3:501-8.
39. Karnes WE, Samloff IM, Siurala M, Kekki M, Sipponen P, Kim SW, Walsh JH. Positive Serum Antibody and Negative Tissue Staining for *Helicobacter pylori* in Subjects with Atrophic Body Gastritis. *Gastroenterology* 1992;101:167-174.
40. Sipponen P, Graham DY. Importance of atrophic gastritis in diagnostics and prevention of gastric cancer: application of plasma biomarkers. *Scand. J. Gastroenterol*. 2007;42 (1);2-10.
41. Varis K, Sipponen P, Laxén F, Samloff M, Huttunen JK, Taylor PR, Heinonen OP, Albanes D, Sande N, Virtamo J, Härkönen M & the Helsinki Gastritis Study Group. Implications of Serum Pepsinogen I in Early Endoscopic Diagnosis of Gastric Cancer and Dysplasia. *Scand J Gastroenterol* 2000; 35:950-956.
42. [http://www.ddw-online.com/therapeutics/310430/opportunités\\_in\\_gastroenterology.html](http://www.ddw-online.com/therapeutics/310430/opportunités_in_gastroenterology.html)
43. <http://nobelprize.org/medicine/laureates/2005/press.html>
44. [http://www.yourhealthbase.com/database/rulcer\\_drugs.htm](http://www.yourhealthbase.com/database/rulcer_drugs.htm)
45. [www.biohit.com/ About Us / History: Aggressive innovation and patenting strategy](http://www.biohit.com/ About Us / History: Aggressive innovation and patenting strategy)